

Prophylactic and temporary inferior vena cava filter implantation in trauma

Implante profilático e temporário de filtro de veia cava inferior no trauma

Fábio Augusto Cypreste Oliveira¹, Carlos Eduardo de Sousa Amorelli¹, Fábio Lemos Campedelli¹, Juliana Caetano Barreto², Mariana Caetano Barreto³, Philippe Moreira da Silva⁴, Fernanda Lauar Sampaio Meirelles⁵

Abstract

Pulmonary embolism is a major cause of death after traumas and, in the majority of trauma cases, the anticoagulation drugs usually employed for prevention and treatment of pulmonary embolisms are contraindicated. We report on a case in which a prophylactic and temporary inferior vena cava filter (VCF) was implanted in a multiple trauma patient at high risk of pulmonary embolism.

Keywords: vena cava inferior; wounds and injuries; pulmonary embolism.

Resumo

O tromboembolismo pulmonar (TEP) é importante causa de óbito no trauma e esse, na maioria das vezes, contraindica a principal farmacoterapia na prevenção e no tratamento do TEP: a anticoagulação. Relatamos um caso de paciente politraumatizado, com risco elevado de embolia pulmonar, submetido ao implante preventivo e temporário de filtro de veia cava inferior (FVC).

Palavras-chave: veia cava inferior; ferimentos e lesões; embolia pulmonar.

¹Sociedade Brasileira de Angiologia e Cirurgia Vascular (SBACV), Colégio Brasileiro de Radiologia (CBR), Associação Médica Brasileira (AMB), Goiânia, GO, Brazil.

²Serviço de Angiologia, Cirurgia Vascular, Endovascular e Laserterapia (Angiogyn), Goiânia, GO, Brazil.

³Hospital de Urgências de Goiânia, Goiânia, GO, Brazil.

⁴Angiogyn, Goiânia, GO, Brazil.

⁵Pontifícia Universidade Católica de Goiás - PUC-Goiás, Goiânia, GO, Brazil.

Financial support: None.

Conflict of interest: No conflicts of interest declared concerning the publication of this article.

Submitted on: 03.09.11. Accepted on: 26.06.2012

■ INTRODUCTION

Venous thromboembolisms are responsible for elevated mortality and morbidity in multiple trauma patients and can occur in more than 50% of cases¹⁻³. Pneumatic compression and administration of low doses of heparin are indicated in these patients, but questions have been asked about their overall efficacy for prevention of pulmonary embolisms (PE) after multiple traumas^{4,5} and their use may need to be suspended in such cases, even if only temporarily. The incidence rates of PE and their complications are higher in the first days after trauma. During this period, the vena cava should be interrupted and fitting an infrarenal vena cava filter is the main defense against pulmonary embolism⁶.

■ CASE REPORT

T.L., a 66-year-old male with hypertension, obesity (body mass index of 33) and a long-term smoking habit, suffered multiple traumas in a tractor accident and was admitted to our department with hypovolemic shock. The patient was initially treated in accordance with protocols that are established worldwide and transferred to intensive care (IC) after volemic resuscitation.

Secondary examinations revealed the following: mild traumatic brain injury, closed fracture of the left femoral diaphysis, fracture with luxation of pelvis and thorax – left side instable due to multiple rib fractures and hemopneumothorax with low output via a chest drain with water seal. The left leg was put in orthopedic traction and 12 hours after the patient was first seen, when he was already stable hemodynamically and on intermittent pneumatic compression, an ELLA[®] (Ella – CS) retrievable infrarenal vena cava filter was implanted via the right jugular and a double-lumen catheter was fitted via the same route.

The patient enjoyed satisfactory progress; hemodynamic stability was maintained, thoracic drainage output reduced progressively and his ventilation profile improved. Definitive surgical correction of the femoral fracture was conducted on the eighth day in hospital and the patient was discharged from the IC breathing spontaneously via a tracheostomy after the thoracic drain had been removed.

On the twelfth day in hospital, the vena cava filter was removed via the right jugular using a Multi-snare[®] loop (PFM Medical) and a 12F long introducer sheath (Figures 1 and 2). Thrombi were found adhered to the filter (Figure 3).

The patient was discharged from hospital after 15 days with no signs of deep venous thrombosis or pulmonary embolism and intermittent pneumatic compression and subcutaneous low-dose, low molecular weight heparin were kept at outpatients levels until he was able to walk again. Outpatients follow-up at our clinic 30 days after the trauma revealed no vascular complications.

■ DISCUSSION

Multiple trauma patients are at high risk of developing PE, particularly in cases in which anticoagulant drugs cannot be used^{7,8}. Some studies have advocated preventative (in the absence of proven deep venous thrombosis or pulmonary

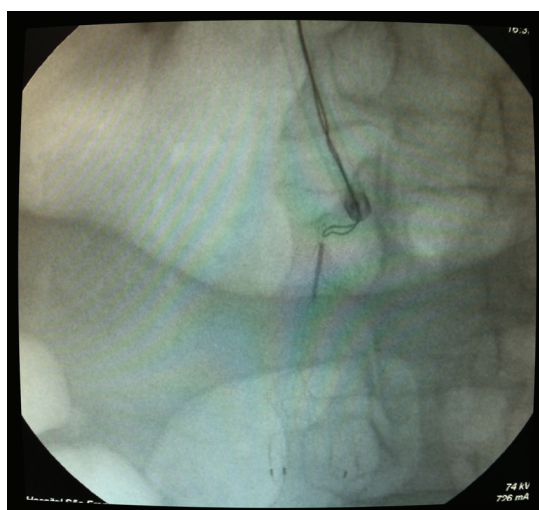


Figure 1. Using the Multi-snare[®] loop to catch the filter.

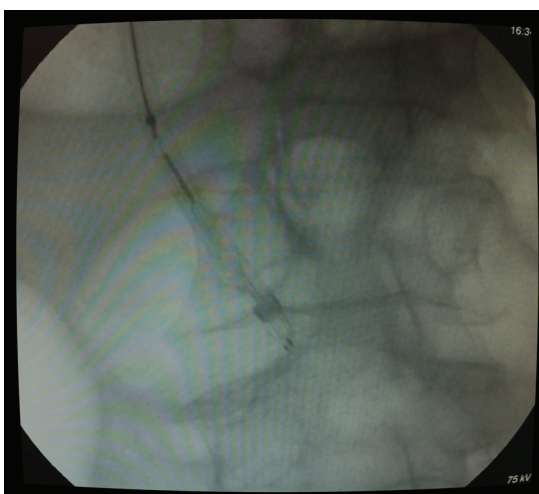


Figure 2. Retrieving the filter using the 12F sheath.

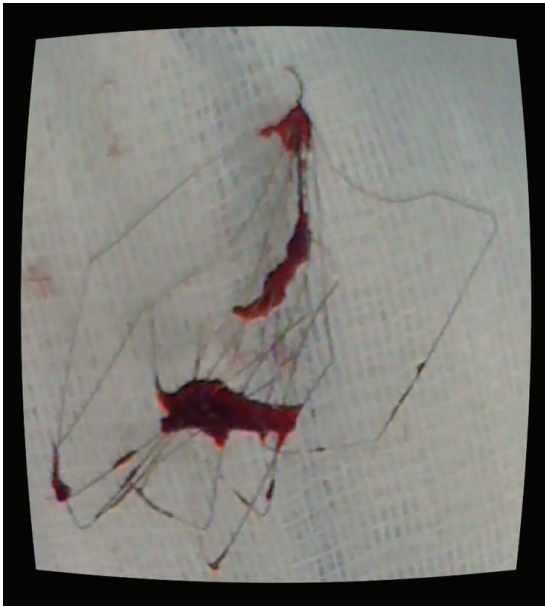


Figure 3. Retrieved ELLA® filter with thrombus inside.

embolism) implantation of a vena cava filter after a trauma, on the basis that it reduces the incidence of severe thromboembolic events in these cases and because it involves temporary interruption of the vena cava⁹⁻¹². The majority of filters are fitted with the aid of fluoroscopy, using iodine-based contrasts in specific sectors, but for patients at high risk from transportation, they can be fitted at the bedside with the aid of vascular Doppler ultrasound¹³.

The rate of removal of retrievable filters is still low, which can be attributed to the clinical conditions of multiple trauma patients and to failures by the services that implant filters to follow-up their patients afterwards¹⁴.

Permanent vena cava filters offer high efficacy for prevention of PE, but are not themselves free from complications and there is a significant rate of thrombosis, which in turn can lead to severe post-thrombotic complications^{15,16}. In view of this, temporary interruption of the vena cava with a filter appears to be the best option for preventing PE, particularly in cases in which full anticoagulation is contraindicated¹⁷. Mechanical compression techniques (elastic stockings and intermittent pneumatic compression) should be used routinely whenever possible.

We have reported on a case of a multiple trauma patient at high risk of PE for whom anticoagulation was contraindicated, requiring temporary implantation of an infrarenal vena cava

filter which successfully prevented PE for 30 days after the trauma without complications.

■ ACKNOWLEDGEMENTS

We are grateful to Dr. Vasco Lauria da Fonseca Filho, head of the vascular and endovascular surgery department at the Hospital da Lagoa (RJ), for always having something new to teach us and for providing specific material for our literature review.

■ REFERENCES

1. Dries DJ. Activation of the clotting system and complement after trauma. *New Horiz.* 1996;4:276-89.
2. Weinmann EE, Salzman EW. Deep-vein thrombosis. *N Engl J Med.* 1994;331:1630-41.
3. Geerts WH, Jay RM, Code KJ, et al. A comparison of low-dose heparin with low-molecular-weight heparin as prophylaxis against venous thromboembolism after major trauma. *N Engl J Med.* 1996;335:701-7. PMID:8703169.
4. Winchell RJ, Hoyt DB, Walsh JC, Simons RK, Eastman AB. Risk factors associated with pulmonary embolism despite routine prophylaxis: implications for improved protection. *J Trauma.* 1994;37(4):600-6. PMID:7932891.
5. Knudson MM, Collins JA, Goodman SB, McCrory DW. Thromboembolism following multiple trauma. *J Trauma.* 1992;32(1):2-11. PMID:1732568.
6. Carlin AM, Tyburski JG, Wilson RF, Steffes C. Prophylactic and therapeutic inferior vena cava filters to prevent pulmonary emboli in trauma patients. *Arch Surg.* 2002;137:521-7. PMID:11982463
7. Stawicki SP, Grossman MD, Cipolla J, et al. Deep venous thrombosis and pulmonary embolism in trauma patients: an overstatement of the problem? *Am Surg.* 2005;71:387-91. PMID:15986967.
8. Sevitt S, Gallagher N. Venous thrombosis and pulmonary embolism. A clinic-pathological study in injured and burned patients. *Br J Surg.* 1961;48:475-89.
9. Webb LX, Rush PT, Fuller SB, Meredith JW. Greenfield filter prophylaxis of pulmonary embolism in patients undergoing surgery for acetabular fracture. *J Orthop Trauma.* 1992;6:139-54. PMID:1602332.
10. Rosenthal D, McKinsey JF, Levy AM, Lamis PA, Clark MD. Use of Greenfield filter in patients with major trauma. *Cardiovasc Surg.* 1994;2:52-5.
11. Matous SK, Puyana JC, Castle JM. The use of the inferior vena cava filter in trauma patients. In: *Proceedings of the 24th Annual Scientific Meeting of the Western Trauma Association; March 3, 1994; Crested Butte, Colo. Crested Butte; 1994.*
12. Rodriguez JL, Lopez JM, Proctor MC, et al. Early placement of prophylactic vena caval filters in injured patients at high risk for pulmonary embolism. *J Trauma.* 1996;40(5):797-804. PMID:8614083.
13. Nesar RA, Capasso Filho M, Homa CMO. Implante de filtro de veia cava guiado por ultra-som: relato de dois casos. *J Vasc Bras.* 2006;5(1):71-3. <http://dx.doi.org/10.1590/S1677-54492006000100014>
14. Coimbra R, Constantini T. Retrievable inferior vena cava filter use in trauma: has the fever broken? *J Vasc Bras.* 2009;8(3):204-6. <http://dx.doi.org/10.1590/S1677-54492009000300003>

15. Geerts WH, Code KI, Jay RM, Chen E, Szalai JP. A prospective study of venous thromboembolism after major trauma. *N Engl J Med* 1994;331:1601-6. PMID:7969340.
16. Blebea J, Wilson R, Waybill P, et al. Deep venous thrombosis after percutaneous insertion of vena caval filters. *J Vasc Surg.* 1999;30(5):821-8. [http://dx.doi.org/10.1016/S0741-5214\(99\)70006-6](http://dx.doi.org/10.1016/S0741-5214(99)70006-6)
17. Fonseca Filho VL, Oliveira FAC. Filtro de veia cava-tipos, indicações, técnica e resultados. In: Brito CJ, editor. *Cirurgia vascular cirurgia endovascular angiologia*. 2. ed. Revinter; 2008. p.1727-38.

Correspondence

Fabio Augusto Cypreste Oliveira
Avenida Alphaville Flamboyant, 3900, casa 283,
CEP 74884-527 – Goiânia, GO, Brazil
E-mail: fabioacoliveira@gmail.com

Author information

FACO, CESA, FLC specialist in Vascular Surgery (Angioradiology and Endovascular Surgery), Sociedade Brasileira de Angiologia e de Cirurgia Vascular (SBACV), Colégio Brasileiro de Radiologia (CBR), and Associação Médica Brasileira (AMB).

JCB general practitioner, Angiogyn, Goiânia, Brazil.

MCB general surgeon, Hospital de Urgências de Goiânia, Brazil.

PLS scrub nurse technician, Angiogyn, Goiânia, Brazil.

FLSM medical student (6th year), Pontifícia Universidade Católica de Goiás (PUC Goiás).

Authors contributions

Conception and design: FACO

Analysis and interpretation: FACO, CESA, FLC

Data collection: FACO, JCB, MCB, FLSM, PMS

Writing the article: FACO, JCB, MCB, FLSM

Critical revision of the article: FACO, CESA, FLC

Final approval of the article*: FACO, CESA, FLC, MCB, JCB, FLSM, PMS

Statistical analysis: FACO, CESA, FLC

Overall responsibility: FACO, CESA, FLC

*All authors have read and approved the final version submitted to *J Vasc Bras*.