

## CASE REPORT

---

# Treatment of pelvic congestion associated with varicose veins of the lower limbs: report of a small number of cases

*Tratamento da congestão pélvica associada a varizes dos membros inferiores: relato de uma pequena série de casos*

Fábio Augusto Cypreste Oliveira<sup>1</sup>, Carlos Eduardo de Sousa Amorelli<sup>1</sup>, Fábio Lemos Campedelli<sup>1</sup>, Juliana Caetano Barreto<sup>2</sup>, Mariana Caetano Barreto<sup>3</sup>, Philippe Moreira da Silva<sup>4</sup>, Fernanda Lauer Sampaio Meirelles<sup>5</sup>

### Abstract

The pelvic congestion syndrome is defined by anatomical criteria, hemodynamic and clinical result of hypertension and venocapillary stasis in the pelvic area and can be extended to the lower limbs. The presence of varicose veins of the lower limbs may or may not correlate reflux of the saphenous system and, in cases of absence of saphenous reflux, the reflux pelvic presents itself as an important etiological factor responsible for recurrence of venous disease in lower limbs. The authors report a small series of three cases of young patients suffering from pelvic congestion syndrome associated with varicose veins of the lower limbs treated by pelvic embolization and surgical treatment of varicose veins of the lower limbs during the surgical procedure with good initial results and no embolic complications.

**Keywords:** pelvic pain; embolization, therapeutic; varicose veins.

### Resumo

A síndrome de congestão pélvica é definida por critérios anatômicos, hemodinâmicos e clínicos, decorrentes da hipertensão e estase venocapilar no território pélvico, podendo ser estendido aos membros inferiores. A presença de varizes dos membros inferiores pode estar ou não relacionada ao refluxo do sistema safeno e, nos casos de ausência do refluxo safeno, o refluxo pélvico apresenta-se como importante fator etiológico responsável pelo aparecimento e recidiva da doença venosa nos membros inferiores. Os autores relatam uma pequena série de três casos de pacientes jovens portadoras de síndrome de congestão pélvica associada à varizes dos membros inferiores tratadas por embolização pélvica e tratamento cirúrgico das varizes de membros inferiores, no mesmo tempo cirúrgico, com bons resultados iniciais e ausência de complicações embólicas.

**Palavras-chave:** dor pélvica; embolização terapêutica; varizes.

### Introduction

---

The pelvic congestion syndrome (PCS) has been described since the past century<sup>1</sup>. Its main clinical manifestations are: non-cyclical chronic pelvic pain (>6 months), dyspareunia or post-coital discomfort, pre-menstrual pain, sensation of pelvic/perineal “weight” and menstrual changes associated with the presence of pelvic, perineal and vulvar

varicose veins. PCS can be related to the appearance of lower limb varicose veins in an atypical topography or early recurrence<sup>2-4</sup>. Pelvic congestion can be caused by venous reflux, external compression, secondary to thrombotic occlusions, or a combination of causes, thus determining the “escape” and miscellaneous process, as described in Table 1. According to Monedero et al.<sup>5</sup>, there are multiple connections between the infra-renal and pelvic venous systems with the lower limbs.

---

Study carried out at the Service of Angiology, Vascular Surgery, Endovascular and Laser Therapy of Hospital São Francisco de Assis – Goiânia (GO), Brazil.

<sup>1</sup>Specialist in Vascular Surgery with experience in Endovascular Surgery and Angiography by the Brazilian Society of Angiology and Vascular Surgery (SBACV), of Colégio Brasileiro de Radiologia (CBR) and the Brazilian Medical Association (AMB) – Goiânia (GO), Brazil.

<sup>2</sup>General practitioner at Angiodyn – Goiânia (GO), Brazil.

<sup>3</sup>General Surgeon at Hospital de Urgências de Goiânia – Goiânia (GO), Brazil.

<sup>4</sup>Nursing and Instrumentation Technician at Angiodyn – Goiânia (GO), Brazil.

<sup>5</sup>Medical Student (6<sup>th</sup> year) at Pontifícia Universidade Católica of Goiás (PUC-Goiás) – Goiânia (GO), Brazil.

Financing source: none.

Conflict of interest: nothing to declare.

Submitted on: 08.24.11. Accepted on: 10.28.11.

J Vasc Bras. 2012;11(1):62-66.

**Table 1.** Relation between physiopathology and etiology of pelvic venous congestion

Physiopathology	Etiology
Reflux	Ovarian veins Internal iliac veins Pelvic vascular malformations Post-thrombotic syndrome
External compression	"Nutcracker" syndrome May-Thurner syndrome Pelvic tumors
Occlusion	Chronic iliac vein and inferior vena cava thrombosis

Thus, the pelvic renal reflux can be transmitted to the lower limbs, presenting as recurrent varicose veins. Labropoulos et al.<sup>6</sup> studied 834 limbs and found 84 limbs (10%) of non-saphenous reflux. In that series, the relation with pelvic venous reflux was 34%, and 68% originated in vulvar veins medial to the femoral-saphenous junction, and 32% of gluteal veins.

Lower limb varicose veins with pelvic origin can present in four ways:

1. Sapheno-femoral junction reflux;
2. Reflux to the *saphena magna* and *saphena parva*;
3. Reflux parallel to the saphenous axis (medial side of the thigh);
4. Sciatic reflux (posterior side of the thigh and gluteal).

Recurrence of lower limb varicose veins of abdominal/pelvic origin may happen in up to 17% of the cases<sup>7,8</sup>.

The diagnosis of PCS is defined by a detailed clinical history and physical examination, including gynecological and perianal exams. Non-invasive vascular testing includes vascular ultrasound with transparietal abdominal/pelvic color Doppler ultrasonography (to analyze the iliac axis, cava and renal) and endovaginal ultrasound (pelvic evaluation) associated with the ultrasonographic study of the lower limbs. Some echographic criteria can define syndromes (May-Thurner and "nutcracker"), according to Engelhorn et al.<sup>9</sup> However, the presence of tributary dilated and tortuous veins in the pelvic adnexal area with diameter  $\geq 7$ mm associated with bidirectional flow during the Valsalva Maneuver and endovaginal ultrasound is diagnostic of pelvic varicose veins<sup>9</sup>. The diagnosis of pelvic venous thrombosis could also be performed with this method.

Pelvic angioresonance has been used as the non-invasive diagnostic method of choice for the anatomical definition of the pelvic congestion, its relation with the lower limb venous system and the etiological definition of PCS. Coakley et al.<sup>10</sup> describe criteria for the angioresonance/angiotomography of pelvic reflux, which include tributary to uterine veins  $>4$  mm, and gonadal vein  $>8$  mm. Pelvic phlebography is not a routine test, used exceptionally and

at endovascular therapy. Beard et al.<sup>11</sup> describe phlebographic criteria: contrast retention  $>20$  seconds, gonadal vein  $>6$ mm and contrast retention in varicose tributaries in the vulva and the perineum. Intravascular ultrasound (USIVU) is mostly used for the differential diagnosis of the "nutcracker" and the May-Thurner syndrome, or when the previously described methods fail.

Once the diagnosis of PCS and chronic venous insufficiency of the lower limbs is confirmed, medical treatment is established with pharmacotherapy, elastic stocking compression, physiotherapy and postural treatment. In refractory cases, invasive treatment is indicated.

## Case report

### Case 1

The patient is a 26-year old multiparous female patient (GIVPIIIAI), with PCS due to left gonadal vein reflux manifested as non-cyclical chronic pelvic pain, dyspareunia and metrorrhagia. At physical examination, she presented with vulvar and perineal varicose veins associated with symptomatic lower limb varicose veins (CEAP classification III) with no saphenous reflux at vascular echography of the lower limbs. Endovaginal ultrasound suggested pelvic varicose veins, especially on the left side, which were confirmed by angioresonance. No sign of external compression or thrombosis was identified. Under spinal anesthesia and sedation, lower limb varicose vein operation was performed, with segmental phlebectomies and insufficient Cockett's perforating vein ligation, followed by embolization of pelvic varicose veins and left gonadal vein with Histoacryl glue and lipiodol 3:1, via right femoral vein, all done in an one-stage procedure (Figures 1 and 2). The procedure was uneventful and the patient was discharged from the hospital after 24 hours, with no changes in the kidney function or signs of pulmonary embolism and no bleeding from the surgical incisions. She has been on outpatient follow-up for 21 months since the operation, presenting significant improvement in pelvic symptoms. She has been asymptomatic and has a satisfactory cosmetic result, with no recurrence of vulvar or lower limb varicose veins.

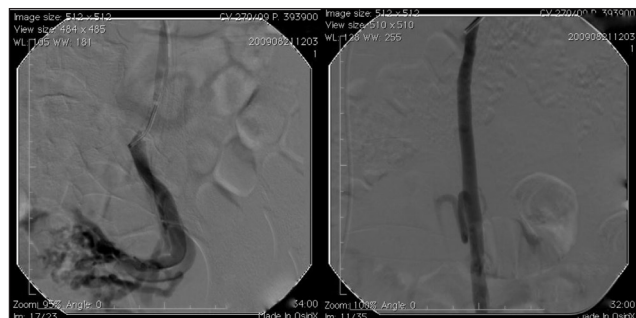
### Case 2

The patient is a 41-year old multiparous female patient (GIVPIVA0), with PCS manifested by non-cyclical chronic pelvic pain, post-coital discomfort and sensation of weight in the lower abdomen. At physical examination, she had symptomatic vulvar, gluteal and lower limb varicose

veins (CEAP classification III), (Figure 3). Doppler ultrasonography showed left *saphena magna* reflux of both lower limbs. She underwent endovaginal ultrasound that was suggestive of pelvic varicose veins. The diagnosis was confirmed by angioresonance which showed reflux in the internal right iliac vein with contrast retention in tributary varicose veins due to probable reflux along the sciatic nerve. There were no signs of external compression or thrombosis. Under spinal anesthesia and sedation, surgery of varicose veins in the lower limbs with segmental phlebectomy and thermal ablation of the left saphena magna with semiconductor laser (980 nm of wavelength and 30 watts of power with 600 micron fiber) was performed, followed by embolization of tributary pelvic varicose veins in the internal right iliac vein and its trunk with histoacryl and Gianturco coils, via right femoral vein. The procedure was uneventful and the patient was discharged from the hospital after 24 hours, with no changes in the kidney function or signs of pulmonary embolism and no bleeding from the surgical incisions. She has been on outpatient follow-up for 18 months since the operation, with significant improvement of pelvic symptoms, and asymptomatic in the lower limbs with satisfactory cosmetic results, with no varicose veins recurrence.

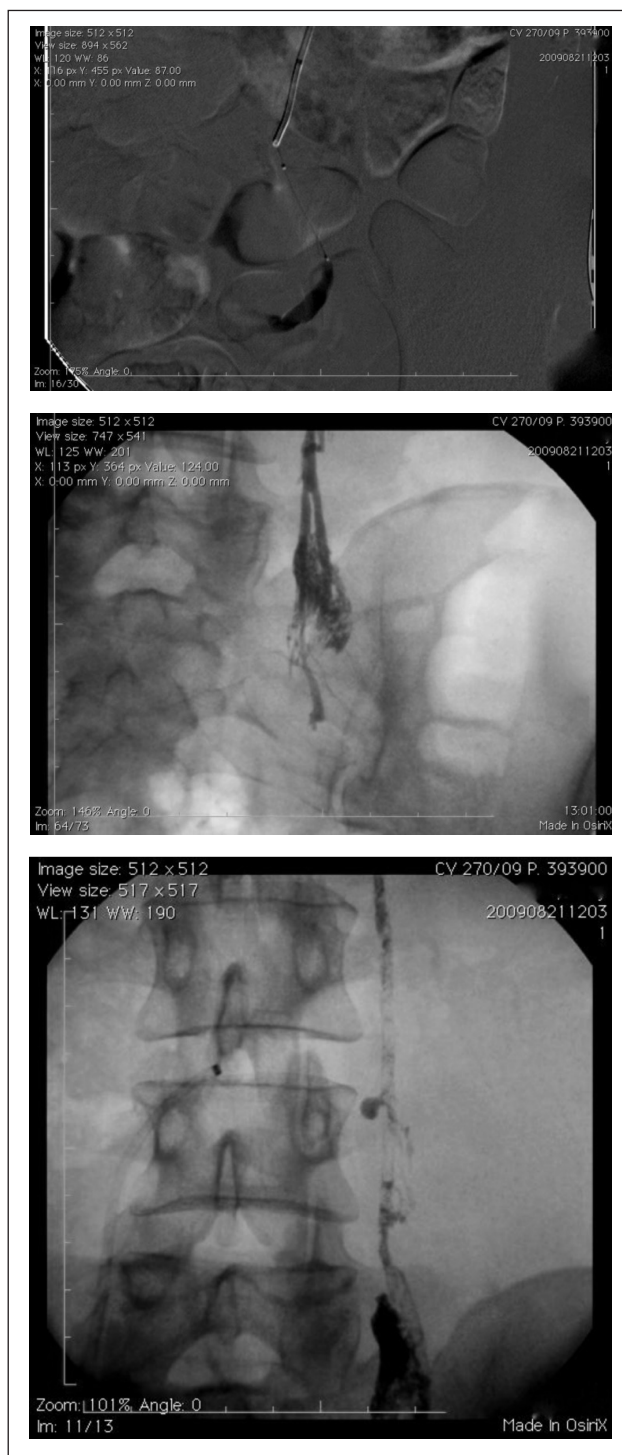
### Case 3

The patient is a 28-year-old multiparous female patient (GIIPIIIA0), with PCS due to left gonadal vein manifested by non-cyclical chronic pelvic pain, dyspareunia and metrorrhagia. Physical examination showed vulvar and perineal varicose veins associated with symptomatic lower limb varicose veins (CEAP classification III). No saphenous vein reflux was seen at Doppler ultrasonography of the lower limbs. An endovaginal ultrasound was suggestive of pelvic varicose veins. Angioresonance confirmed the echographic findings and also identified an incompetent left ovarian vein. There were no signs of external compression

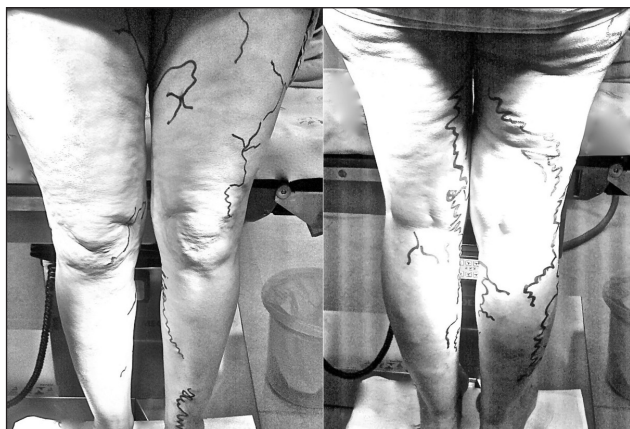

**Figure 1.** Selective venography of left ovarian vein with reflux and pelvic varicose vein filling with contrast retention.

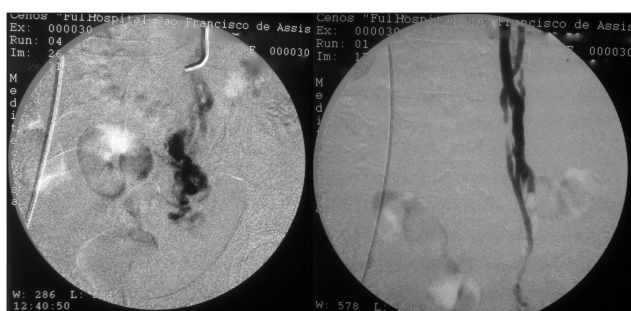
or thrombosis. Under spinal anesthesia and sedation, operation on the lower limbs varicose veins, with segmental phlebectomy followed by embolization of pelvic varicose veins and left gonadal vein with histoacryl and Gianturco coils, via right femoral vein were performed (Figures 4 and 5).



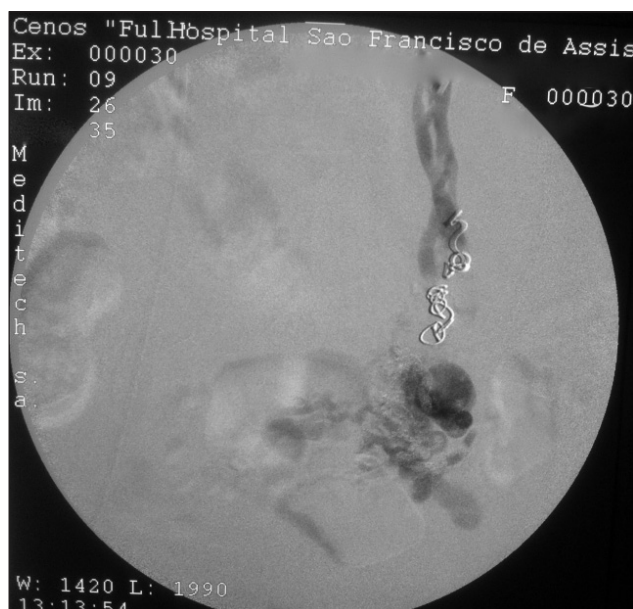**Figure 2.** Superselctive catheterization with microcatheter and injection of lipiodol and histoacryl 3:1, with distal to proximal embolization.



**Figure 3.** Demonstration of reflux to the lower limbs. It is important to observe the prevalence in the posterior side of the thigh and buttocks due to reflux originated in the tributaries of internal iliac vein.



**Figure 4.** Selective phlebography of left gonadal vein presenting as duplicated, tortuous, dilated and incompetent, with reflux and pelvic contrast retention.



**Figure 5.** Superselective catheterization with mixed embolization, in the varicose plexus with glue and in the proximal gonadal stem with Ginturco coils. Control venography without filling of the varicose plexus.

The procedure was uneventful and the patient was discharged from the hospital after 24 hours, with no changes in the kidney function, or signs of pulmonary embolism and no bleeding from the surgical incisions. She has been on outpatient follow-up for two months since the operation, with significant improvement of pelvic symptoms, and asymptomatic in the lower limbs with satisfactory cosmetic results, with no varicose veins recurrence.

## Discussion

Several techniques have been described to treat the symptoms of PCS that are refractory to the initial therapy. The classical treatment consists of the surgical ligation by retroperitoneal access of gonadal and/or internal iliac veins<sup>12</sup>. Laparoscopic ligation of pelvic veins is feasible, with improvement of abdominal symptoms, and it is also an important method in the differential diagnosis of causes for chronic pelvic pain<sup>13</sup>. Embolization of tributary varicose veins and venous trunks has been showing satisfactory results, comparable to surgical ligation in the clinical control of PCS, with lower morbidity rates and length of hospital stay<sup>14</sup>. In cases of external compression or chronic iliac vein and inferior vena cava thrombosis, simple angioplasty, or with a stent, has been performed with satisfactory initial results<sup>15,16</sup>. Hysterectomy, with or without oophorectomy, will only be indicated when the previously described therapeutic options have failed.

We could not find any contraindications or factors that increase the morbidity rates of surgical treatment of lower limb varicose veins associated with the endovascular treatment of PCS. Thus, we chose to treat PCS and chronic venous insufficiency of the lower limbs at the same time, with the goal of performing the definitive treatment under a single anesthetic session and hospital admission, thus lowering the patients' surgical risk.

## Conclusion

The synchronous treatment of the pelvic congestion syndrome by percutaneous embolization, and lower limb varicose veins by surgery is feasible, with good initial results and low complication rates, however, we need more cases and long term follow-up.

## References

1. Taylor Jr HC. Vascular congestion and hyperhemia: the effect on function in the female reproductive organs. Part I. Physiological basis and history of the concept. *Am J Obstet Gynecol.* 1949;57:211-30.

2. Greiner M, Gillin-Smith GL. Leg varices originating from the pelvis: diagnosis and treatment. *Vascular*. 2007;15(2):70-8.
3. Creton D, Hennequin L, Kohler F, et al. Embolisation of symptomatic pelvic veins in women presenting with non-saphenous varicose veins of pelvic origin - three-year follow-up. *Eur J Vasc Endovasc Surg*. 2007;34(1):112-7.
4. Engelhorn CA, Engelhorn AL, Cassou MF, et al. Classificação anatomofuncional da insuficiência das veias safenas baseada no eco-Doppler colorido dirigida para o planejamento cirúrgico das varizes. *J Vasc Br*. 2004;3(1):13-9.
5. Leal Monedero J, Zubicoa Ezpeleta S, Castro Castro J et al. Embolization treatment of recurrent varices of pelvic origin. *Phlebology*. 2006;1(1):3-11.
6. Labropoulos N. Nonsaphenous superficial vein reflux. *J Vasc Surg*. 2001;34(5):872-7.
7. Van Rij AM, Jiang P, Solomon C, et al. Recurrence after varicose vein surgery (a prospective long-term clinical study with duplex ultrasound scanning and air plethysmography). *J Vasc Surg*. 2003;38:935-43.
8. Perrin MR, Labropoulos N, Leon LR Jr. Presentation of the patient with recurrent varices after surgery (REVAS). *J Vasc Surg*. 2006;43(2):327-34.
9. Engelhorn CA, Morais-Filho DM, Barros FS, et al. Investigação da síndrome de quebra-nozes e Síndrome compressiva da veia íliaca comum esquerda pela artéria íliaca comum direita. Engelhorn CA, Morais-Filho DM, Barros FS, et al. Guia prático de ultrassonografia vascular. 2. ed. Rio Janeiro: Di Livro, 2011. p. 213-26.
10. Coakley FV, Varghese SL, Hricak H. CT and MRI of pelvic varices in women. *Journal of Computer Assisted Tomography*. 1999;23(3):429-34.
11. Beard RW, Highman JH, Pearce S, et al. The diagnosis of pelvic varicosities in women with chronic pelvic pain. *Lancet*. 1984;2:946-9.
12. Edwards RD, Robertson AB, MacLean AB, et al. Case report pelvic pain syndrome - successful treatment of a case by ovarian vein embolization. *Clin Radiol*. 1993;47:429-31.
13. Mathis BV, Miller JS, Lukens ML, et al. Pelvic congestion syndrome: a new approach to an unusual problem. *Am Surg*. 1995;61:1016-8.
14. Cordts PR, Eclavea A, Buckley PJ, et al. Pelvic congestion syndrome: early clinical results after transcatheter ovarian vein embolization. *J Vasc Surg*. 1998;28:862-8.
15. Ferreira M, Lanziotti L, Abuhadba G, et al. Dor pélvica crônica: o papel da síndrome do quebra-nozes. Chronic pelvic pain: the role of the nutcracker syndrome. *J Vasc Bras*. 2008;7(1):76-9.
16. Cunha Júnior JR, Neves DQ, Fontes FA, et al. Tratamento endovascular da síndrome de compressão da veia íliaca (May-Thurner) – relato de caso. *J Vasc Bras*. 2011;10(1):1-5.

---

**Correspondence**

Fabio Augusto Cypreste Oliveira  
Avenida Alphaville Flamboyant, 3.900, casa 283  
CEP 74884-527 – Goiânia (GO), Brazil  
E-mail: fabioacoliveira@gmail.com

**Author's contribution**

Study conception and design: FACO  
Data analysis and interpretation: FACO, CESA, FLC  
Data collection: FACO, JCB, MCB, FLSM, PMS  
Writing: FACO, JCB, MCB, FLSM  
Critical analysis: FACO, CESA, FLC  
Final approval\*: FACO, CESA, FLC  
Statistical analysis: FACO, CESA, FLC  
Overall responsibility: FACO, CESA, FLC

All authors have read and approved the final version submitted to J Vasc Bras.