

Cryoplasty for the treatment of femoropopliteal arterial disease

Crioplastia para tratamento da doença arterial femoro-poplítea

Marco Antonio Lourenço¹, Gustavo Ioshio Handa¹

Abstract

Background: Endovascular treatment of peripheral arterial disease (PAD) presents low morbidity and mortality rates; however, mid and long-term patency rates remain controversial. Cryoplasty was developed as an attempt to resolve the main problems related to angioplasty: dissection, recoil and restenosis.

Objective: To evaluate clinical results and mid-term patency in patients treated with cryoplasty of femoropopliteal arterial disease.

Methods: Patients with indication for endovascular lower limb revascularization according to Fontaine and Rutherford clinical classifications and to TASC II anatomical classification underwent cryoplasty using the PolarCath® peripheral dilatation balloon catheter. Clinical results and anatomical patency were analyzed by duplex ultrasound scan at follow-up.

Results: Ten patients with femoropopliteal arterial disease were treated with cryoplasty. Nine patients presented with intermittent claudication and one patient had an ischemic ulcer. Three patients had class B lesions and seven patients had class A lesions according to the TASC II. Initial technical success was achieved in all patients, and one patient needed stenting during the procedure due to dissection. One patient died due to complications in the postoperative period. Nine patients were followed up for 31.6 months on average (18–35), with primary patency rate of 77.7% and secondary patency rate of 100%. All patients were asymptomatic at the end of this period (Fontaine stage I).

Conclusion: Cryoplasty is a safe technique for the treatment of femoropopliteal arterial disease that presents low morbidity rates, short-term and mid-term results comparable to conventional angioplasty, as well as potential advantages of lower dissection, recoil and mid-term restenosis rates.

Keywords: cryotherapy; angioplasty, balloon; femoral artery.

Resumo

Contexto: O tratamento endovascular da doença arterial obstrutiva periférica apresenta baixa morbidade e mortalidade, no entanto, a perviedade dos *stents* a médio e longo prazo ainda é controversa. A crioplastia foi desenvolvida para reduzir os grandes desafios da angioplastia: dissecação, retração e reestenose.

Objetivo: Avaliar os resultados clínicos e a perviedade a médio prazo em pacientes submetidos à técnica de crioplastia da doença arterial do território femoro-poplíteo.

Métodos: Pacientes com indicação de revascularização de membro inferior por técnica endovascular do território femoro-poplíteo, segundo as classificações clínicas de Fontaine e Rutherford e classificações anatômicas do TASC II, foram submetidos à crioplastia com cateter balão PolarCath®. No seguimento, foram avaliadas as manifestações clínicas e perviedade anatômica pelo *duplex scan*.

Resultados: Dez pacientes foram submetidos à angioplastia do território femoro-poplíteo utilizando a técnica de crioplastia. Nove pacientes apresentavam quadro clínico de claudicação limitante do membro inferior e um paciente apresentava úlcera isquêmica, três pacientes apresentavam lesão classe B pelo TASC II e sete pacientes, classe A. Sucesso técnico angiográfico inicial foi obtido em todos os casos, sendo que um caso necessitou do implante de *stent* devido à dissecação. Seguimento foi realizado em 9 pacientes, por período médio de 31,6 meses (28–35), com perviedade primária de 77,7% e perviedade secundária de 100%. Todos os pacientes apresentam-se assintomáticos no final do seguimento (Fontaine I).

Conclusão: A crioplastia do território femoro-poplíteo é um método seguro, de baixa morbidade, com resultados a curto e médio prazo comparáveis à angioplastia convencional e com potencial de reduzir as taxas de dissecação e retração durante o procedimento, e redução do grau de reestenose a médio e longo prazo.

Palavras-chave: crioterapia; angioplastia com balão; artéria femoral.

Introduction

Endovascular treatment for infrainguinal arterial occlusive disease is well established in literature, presents low morbidity and mortality rates and technical success rate higher than 95%. Indication for treatment is based on clinical manifestations, according to Fontaine and Rutherford classifications, and the option for the endovascular technique is based on TASC II anatomical classification (Transatlantic intersociety consensus for the management of peripheral arterial disease)¹.

Angioplasty with stent placement in the femoropopliteal artery remains controversial. Its use is only indicated in cases of dissection and recoil. The results of primary stenting as to the prevention of mid and long-term restenosis are unfavorable in some studies², but favorable in others³.

Cryoplasty was developed as an attempt to reduce the usual problems related to angioplasty, such as dissection, recoil and restenosis, for it combines the force of balloon dilatation with the cold thermal energy at the vascular wall. Liquid nitrous oxide is used to fill the balloon, which expands and absorbs energy when it turns into gas, thus reducing the temperature of the balloon surface to -10° C.

The effects of cryoplasty involve: 1) changes in plaque response (effect of cooling that freezes the interstitial fluid, forming ice and creating microfractures that break the plaque and contribute to a uniform dilation and less injuries); 2) reduction of elastic recoil (cooling lead to alterations on collagen and elastic fibers, reducing vascular wall elasticity and preventing recoil); 3) apoptosis induction (cooling makes smooth muscle cells to release water, and the dehydration followed by rehydration induces an apoptotic response). This programmed cell death is a non-inflammatory response that may theoretically reduce neointima formation⁴.

Objective

To assess clinical results and mid-term patency in patients subjected to cryoplasty for the treatment of femoropopliteal arterial disease.

Patients and methods

The study was designed as a case series. Consecutive patients who met the inclusion criteria were followed prospectively, and the outcomes were compared with data from the literature and with other treatment techniques.

Control group and randomization techniques were not used.

Patients with indication for lower limb revascularization by an endovascular approach at the femoropopliteal segment — based on the Fontaine and Rutherford clinical classifications and TASC II anatomical classification — underwent cryoplasty with PolarCart® catheter balloon (Boston Scientific). Patients who had been previously treated or had arterial restenosis were excluded from the study.

The cryoplasty technique requires a catheter, a gas-insufflation device with microprocessor and a nitrous oxide storage cylinder (Figures 1 and 2). The traditional technique is performed with the passage of a 0.035 hydrophilic guide wire through a 7Fr sheath and positioning of the cryoplasty balloon at the level of the lesion, followed by release of pressurized liquid nitrous oxide. As it flows into the balloon, the nitrous oxide turns into gas, causing the balloon to expand up to 8 atm of pressure. The temperature at the balloon surface is reduced to -10°C. Each cycle lasts 20 seconds and then the balloon is passively heated and deflated in order to be withdrawn or repositioned (Figure 3). Technical success was defined as less than 30% stenosis at completion angiography. All patients with no contraindications were given acetylsalicylic acid and clopidogrel for 90 days.

Outpatient clinical assessment according to Fontaine and Rutherford classifications was performed one month after the procedure and every six months thereafter after recovery. Anatomical patency was evaluated by duplex scan every six months after the procedure; narrowing exceeding 50% characterized restenosis. Data on morbidity (hemorrhage, local hematoma, pseudoaneurysm formation, arteriovenous fistula, major and minor amputations) and mortality were collected.

All patients signed the informed consent form and agreed to participate in the study and to authorize further data inclusion in clinical trials.

Results

From December 2006 to July 2007, ten patients underwent cryoplasty for femoropopliteal arterial occlusive disease at the Service of Endovascular Surgery, *Santa Casa de Misericórdia de Curitiba*, Curitiba (PR). Nine of them were males and only one was a female patient. Mean age was 60 years (46 to 78 years), and four patients had diabetes mellitus. Nine patients had limiting intermittent claudication of the lower extremity (Fontaine IIb and Rutherford 3), and one presented with ischemic

ulcers (Fontaine IV and Rutherford 6). Based on TASC II classification, seven patients were categorized as A, and three patients as B. All had good run-off and at least one patent distal artery at preoperative angiography.

Initial technical success rate was achieved in all cases, but one patient needed stenting during the procedure due to dissection after balloon insufflation (Figures 4, 5 and 6). Follow-up ended on December 2009 and lasted 31.6 months on average (28 to 35 months). One patient died due to complications and was therefore excluded from the patency assessment. Two patients presented restenosis at the follow-up duplex scan and needed

reintervention. Primary patency rate was 77.77%, and secondary patency was 100%. All patients were asymptomatic (Fontaine I, Rutherford 0) at the end of the follow-up (Figure 7).

No patient had major or minor amputations, and there were no morbidities related to the procedure.

Discussion

Endovascular treatment for femoropopliteal arterial disease by balloon angioplasty presents suboptimal results. Despite the initial technical success rate of more

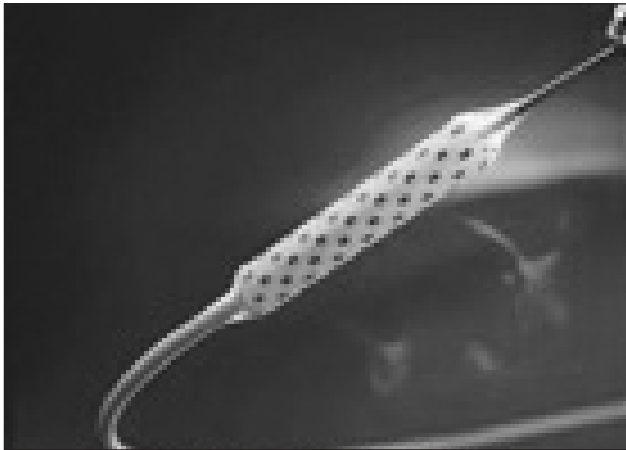
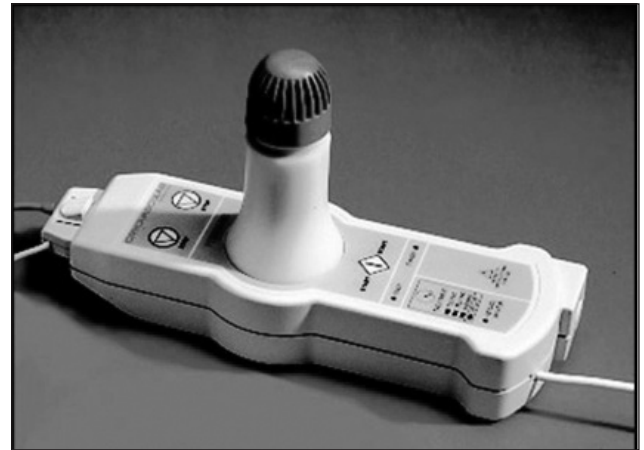


Figure 1. Balloon catheter PolarCath® (Boston Scientific).



Source: <http://www.bostonscientific.com/cryoplasty>

Figure 2. Gas-insufflation device with microprocessor and nitrous oxide cylinder.



Source: <http://www.bostonscientific.com/cryoplasty>

Figure 3. Balloon inflated with nitrous oxide gas reaches pressure at 8 atm and the surface is cooled at -10°C.

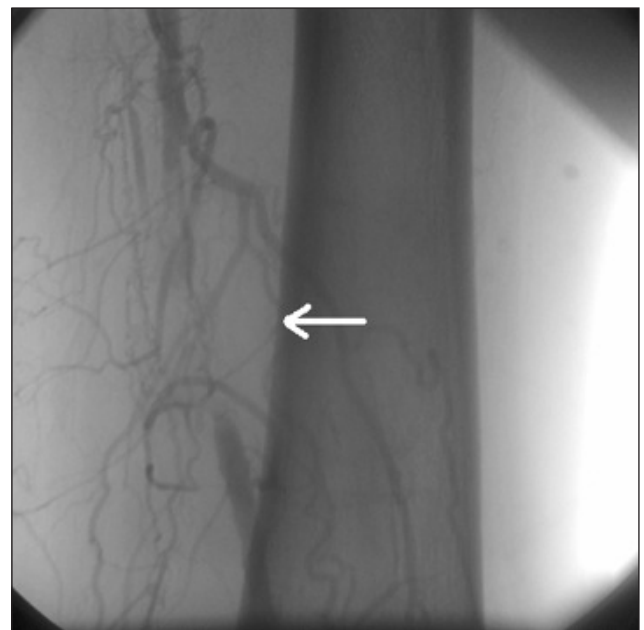

Figure 4. Femoropopliteal arterial occlusion in patient with limiting intermittent claudication (Fontaine IIb, TASC IIa).

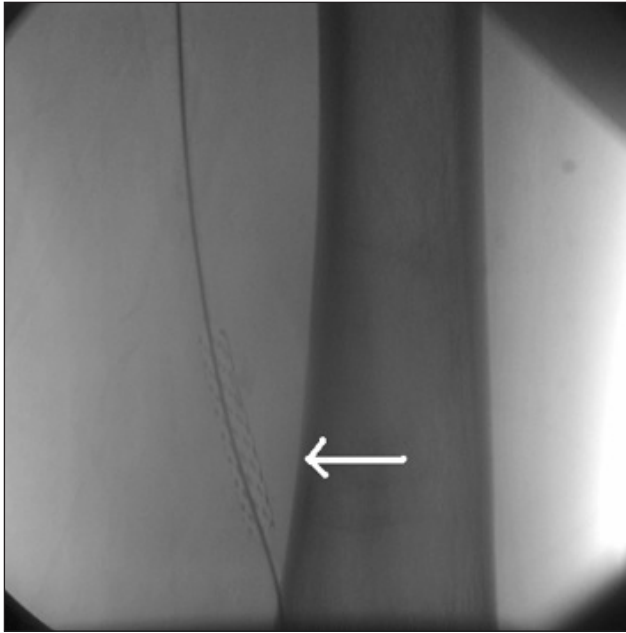


Figure 5. Cryoplasty therapy in the arterial lesion.

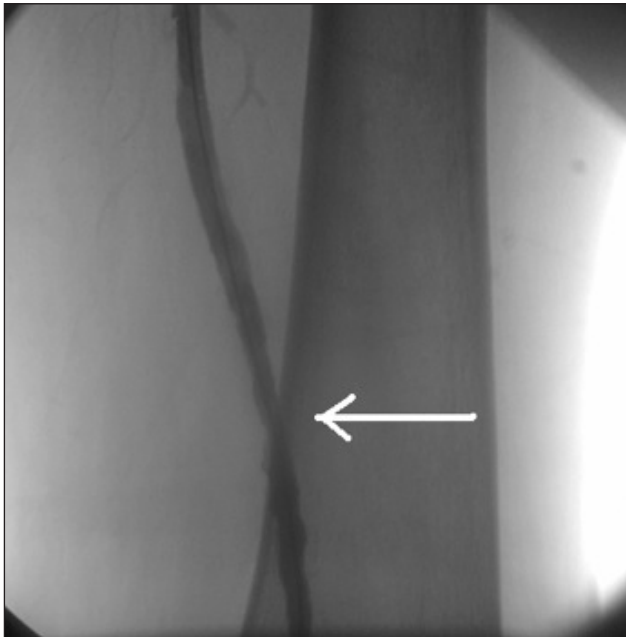


Figure 6. Postoperative angiography showing recanalized artery.

than 95%, restenosis rates range from 40 to 60% after 6 to 12 months⁵, which is much higher compared to other vascular beds, such as the coronary and renal arteries.

Stenting was initially chosen to be performed, but the high rate of restenosis and stent fracture limited its indication to patients with failing simple angioplasties. Stent fractures are associated with a significant reduction in primary patency, and occur as a result of the

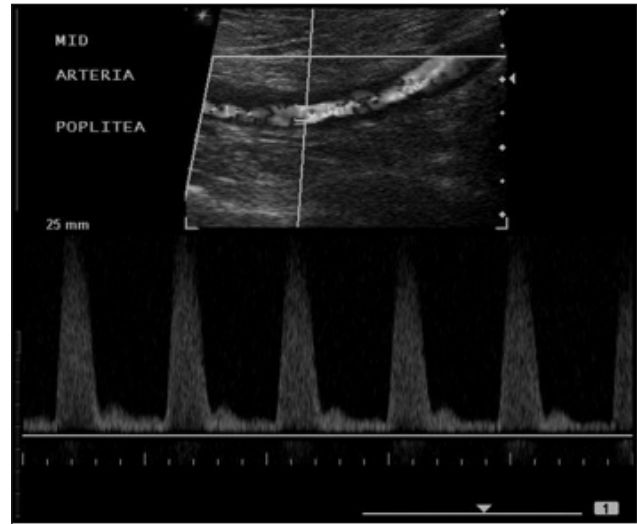


Figure 7. Transversal view of duplex ultrasound scanning at one-year follow-up showing good flow through the popliteal artery and triphasic waveform.

compression, torsion and flexion forces to which the arteries are subjected. Besides that, the treatment of restenosis is difficult, and the placement of stents may compromise a future surgical revascularization^{2,6,7}.

A number of strategies have been developed to create a minimally invasive and long-lasting approach to treat femoropopliteal artery occlusive disease. However, many techniques that were initially promising have not presented satisfactory mid- and long-term results. The use of Sirolimus-coated stents in superficial femoral artery angioplasty (the SIROCCO study) has shown no benefit over non-coated stents⁷. Paclitaxel-coated balloon angioplasty reduced the rate of luminal loss and resulted in better revascularization of the target lesion at six-months in one study, but long-term benefits have not been confirmed⁸.

Cryoplasty combines the time-tested mechanisms of transluminal angioplasty with the biologically favorable effects of cryotherapy. This technique seems to have excellent short and mid-term results, but further long-term studies are needed to determine its actual benefits.

Mechanical-biological effects lead to an altered plaque response to dilation, with reduction of post-dilation recoil and induction of smooth muscle cells apoptosis. Freezing of the plaque and vascular wall causes microfractures, which weakens the plaque and promotes a more uniform dilation, thus reducing the frequency and severity of dissection during the procedure⁹.

Ice formation on the arterial wall produces acute changes in elastin fibers, which are histologically described as fragmentation of elastin fibers and uncoiling of elastic layers that

reduce elastic recoil after cryoplasty². By reducing the rates of dissection and recoil, cryoplasty diminishes the need for femoropopliteal stenting, thereby reducing costs and prolonging patency. Smooth muscle cells apoptosis promoted by cryoplasty results from their exposure to freeze-induced dehydration followed by rehydration and the creation of a hypertonic environment. High apoptotic activity in smooth muscle cells may reduce neointima formation and restenosis^{10,11}.

Laird et al.² conducted a prospective multicenter study to assess the efficacy of cryoplasty for femoropopliteal disease in 102 patients presenting with claudication and lesions less than 10 cm. Technical success was obtained in 85.3% of the patients, with mean residual restenosis of 11.2±11.2% and clinical patency of 82.2% at 9 months (absence of target lesion revascularization), and primary patency of 70.1% at duplex ultrasound scan. The authors followed 70 patients for an average of 31 months and noted a patency rate of 83.2%, patency rate in three years (36 months) estimated in 75%.

A Cochrane database review did not retrieve any randomized controlled trials on cryoplasty. The authors conclude there are no data to support the benefits of the technique over conventional angioplasty, but the rates of technical success and primary patency in prospective studies are encouraging and may suggest a future important role for cryoplasty in the treatment of peripheral arterial obstructive disease (PAOD)¹².

Krajcer et al.¹³ performed 35 successful cryoplasties, including cases of restenosis, anastomotic stenosis and infrapopliteal stenosis, but one patient needed stenting to improve a suboptimal result. Kasper et al.¹⁴ performed 81 cryoplasties in 77 patients. After a mean follow-up of 10.8 months, primary patency was 85% and secondary patency was 89%. Stent was necessary in 12% of the original procedures. A total of 18% of the patients presented restenosis in the follow-up period and needed reintervention.

According to TASC II data, based on randomized trials and meta-analyses, conventional angioplasty presents patency one-year and three-year patency rates of 77 and 61% for stenosis, and 65 and 48% for occlusion, respectively. Stent angioplasty has similar patency rates: 75 and 66% for stenosis, and 73 and 64% for occlusion in one and three years, respectively^{1,15,16}. Cryoplasty presents similar or better patency results than conventional or stent angioplasty, as shown in this series and other studies found in the literature.

Conclusion

Cryoplasty is a safe method for the treatment of femoropopliteal occlusive lesions. This technique presents low morbidity rates, and short- and mid-term results

comparable to conventional angioplasty. It has the potential to reduce dissection, recoil, and the mid and long-term rates of restenosis. However, further randomized controlled trials with longer follow-up are necessary to determine the actual role of cryoplasty in the treatment of peripheral arterial obstructive disease.

References

1. Norgren L, Hiatt WR, Dormandy JA, et al. Inter-society consensus for the management of peripheral arterial disease (TASC II). *J Vasc Surg.* 2007;45(Suppl S):S5-67.
2. Laird JR, Biamino G, McNamara T, et al. Cryoplast for the treatment of femoropopliteal arterial disease: extended follow-up results. *J Endovasc Ther.* 2006;13(Suppl 2):II52-9.
3. Schillinger M, Sabeti S, Loewe C, et al. Balloon angioplasty versus implantation of nitinol stents in the superficial femoral artery. *N Engl J Med.* 2006;354(18):1879-88.
4. Laird JR, Jaff MR, Biamino G, et al. Cryoplasty for the treatment of femoropopliteal arterial disease: results of a prospective multicenter registry. *J Vasc Interv Radiol.* 2005;16(8):1067-73.
5. Minar E, Pokrajac B, Maca T, et al. Endovascular brachytherapy for prophylaxis of restenosis after femoropopliteal angioplasty: results of a prospective randomized study. *Circulation.* 2000;102(22):2694-9.
6. Scheinert D, Scheinert S, Sac J, et al. Prevalence and clinical impact of stent fractures after femoropopliteal stenting. *J Am Coll Cardiol.* 2005;45(2):312-5.
7. Duda SH, Bosiers M, Lammer J, et al. Sirolimus-eluting versus bare nitinol stent for obstructive superficial femoral artery disease: the SIROCCO II trial. *J Vasc Interv Radiol.* 2005;16(3):331-8.
8. Tepe G, Zeller T, Albrecht T, et al. Local delivery of paclitaxel to inhibit restenosis during angioplasty of the leg. *N Engl J Med.* 2008;358(7):689-99.
9. Zhang A, Cheng S, Lei D, et al. An experimental study of the mechanical behavior of frozen arteries at low temperatures. *Cryo Letter.* 2002;23(6):389-96.
10. Tatsutani KN, Joye JD, Virmani R, et al. In Vitro evaluation of vascular endothelial and smooth muscle cell survival and apoptosis in response to hypothermia and freezing. *Cryo Letters.* 2005;26(1):55-64.
11. Isner JM, Kearney M, Bortman S, et al. Apoptosis in human atherosclerosis and restenosis. *Circulation.* 1995;91(11):2703-11.
12. McCaslin JE, Macdonald S, Stansby GP. Cryoplasty for peripheral vascular disease. *Cochrane Database of Systematic Reviews.* 2007; Issue 4. Art. No.: CD005507. DOI: 10.1002/14651858.CD005507.pub2.
13. Krajcer Z, Strickman N, Mortazavi A, Achari A, Dougherty K. Could cryoplasty be a simple solution to fibrointimal hyperplasia in endovascular restenosis? *J Endovasc Ther.* 2005;12 Suppl 1:1-21.
14. Kasper G, Clark PM. Cryoplasty therapy for critical limb ischemia and claudication. *J Endovasc Ther.* 2006;13 Suppl 1:I-13-4.
15. Muradin GS, Bosch JL, Stijnen T, Hunink MG. Balloon dilation and stent implantation for treatment of femoropopliteal arterial disease: meta-analysis. *Radiology.* 2001;221(1):137-45.

16. Cejna M, Thurnher S, Illiasch H, et al. PTA versus Palmaz stent placement in femoropopliteal artery obstructions: a multi-center prospective randomized study. J Vasc Interv Radiol. 2001;12(1):23-31.

Correspondence

Gustavo Ioshio Handa
Rua Chichorro Júnior, 364, apto 1.104 – Cabral
CEP 80035-040 – Curitiba (PR), Brasil.
E-mail: gustavohanda@yahoo.com.br

Author's contribution

Conception and design: MAL
Analysis and interpretation: GIH
Data collection: GIH
Writing the article: GIH
Critical revision of the article: MAL
Final approval of the article*: MAL, GIH
Statistical analysis: GIH
Overall responsibility: MAL

*All authors have read and approved the final version of the article submitted to J Vasc Bras