

Clinical discussion of the arteria lusoria: a case report

Discussão clínica a respeito da artéria lusória: um relato de caso

Tulio Fabiano de Oliveira Leite¹, Lucas Alves Sarmento Pires², Rafael Cisne³, Marcio Antonio Babinski², Carlos Alberto Araujo Chagas³

Abstract

The right subclavian artery may originate from the left portion of the aortic arch. This aberrant vessel is known as the arteria lusoria. Its course to its usual site runs behind the esophagus, which may cause a disease known as dysphagia lusoria, responsible for symptoms of discomfort. This artery is often associated with other anomalies, such as the non-recurrent laryngeal nerve and the bicarotid trunk, and with diseases such as aneurysms, congenital heart defects, and even genetic syndromes. During routine dissection of a male cadaver fixed in 10% formalin solution, an arteria lusoria was found. This article reports the variation and discusses its embryological, clinical and surgical aspects.

Keywords: arteria lusoria; right subclavian artery; anatomical variation; case report.

Resumo

Em alguns casos, a artéria subclávia direita pode se originar da porção esquerda do arco aórtico. Esse vaso aberrante é conhecido como artéria lusória. Para chegar em sua região, essa artéria passa posteriormente ao esôfago, e pode ser, portanto, causa de uma doença conhecida como disfagia lusória, desencadeando sintomas desconfortantes. A artéria lusória está frequentemente associada com outras anomalias, como o nervo laríngeo não recorrente e o tronco bicarotídeo, assim como pode estar em associação com aneurismas, defeitos cardíacos congênitos e até síndromes genéticas. Durante dissecação cadavérica de rotina, foi observada a presença dessa artéria em um cadáver do sexo masculino fixado em uma solução de formalina a 10%. O objetivo deste trabalho é relatar a variação conhecida como artéria lusória e trazer destaque para seus aspectos embriológicos, clínicos e cirúrgicos.

Palavras-chave: artéria lusória; artéria subclávia direita; variação anatômica; relato de caso.

¹ Universidade de São Paulo – USP, Faculty of Medicina, Interventional Radiology, São Paulo, SP, Brazil.

² Universidade Federal Fluminense – UFF, Medical Sciences Post Graduation Program, Niterói, RJ, Brazil.

³ Universidade Federal Fluminense – UFF, Morphology Department, Niterói, RJ, Brazil.

Financial support: None.

Conflicts of interest: No conflicts of interest declared concerning the publication of this article.

Submitted: July 19, 2017. Accepted: September 29, 2017.

The study was carried out at Universidade Federal Fluminense (UFF), Niterói, RJ, Brazil.

INTRODUCTION

The aortic arch (AA) usually gives off three branches: the brachiocephalic trunk (from which originate the right subclavian artery [RSA] and right common carotid artery), the left common carotid artery, and, lastly, the left subclavian artery, from right to left.¹ Variations of the AA and its branches are well known in the literature.^{1,2}

The aberrant right subclavian artery (ARSA) or right subclavian retroesophageal artery (RSRA) occurs in 0.5% to 2.5% of cases. It is known as the “arteria lusoria” (AL).³

This vessel’s route to its usual site usually takes a retroesophageal path, although it can sometimes pass anteriorly to the trachea or even between these two structures.^{1,3}

Due to this trajectory, the AL is of clinical interest because it can cause esophageal compression and symptoms of dysphagia - a condition known as dysphagia lusoria - or dyspnea.³⁻⁶

This aberrant vessel also has surgical significance, because of its spatial relations to many structures, and it can be damaged during surgical procedures.^{7,8}

Although it is usually silent and most cases observed are incidental findings during autopsies, the variation is commonly seen together with a non-recurrent laryngeal nerve and other embryological development abnormalities of the AA complex or the carotid or pulmonary systems.^{9,10}

Studies show that the arteries derived from the fourth arch may have abnormalities in their walls, which is why they could be subject to specific anomalies and pathologies and aortic tears or dissection are also more likely to occur when the AL is present.^{11,12} Additionally, Kommerel’s diverticulum may also coexist with the AL.¹²

This article reports an AL found in a male cadaver and discusses its embryological, clinical, and surgical aspects.

CASE REPORT

A cadaver fixed in 10% formalin solution was dissected during a regular anatomy class. After routine dissection of the right upper limb, the axillary artery was traced and the right subclavian artery was dissected. It was observed that the artery did not originate from the brachiocephalic trunk as usual.

Further dissection revealed that the vessel arose from the distal portion of the AA and followed a retroesophageal trajectory, while the AA presented a bicarotid trunk. The non-recurrent laryngeal nerve was present (Figure 1). No other variations were observed.

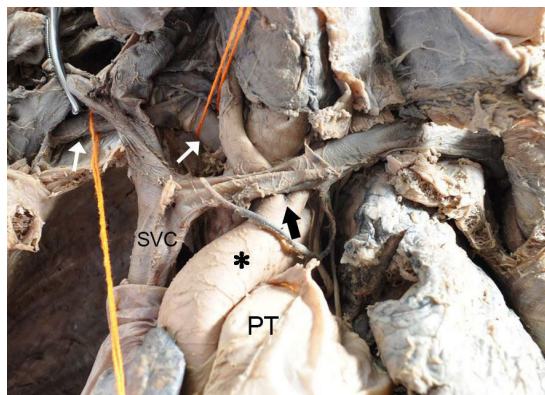


Figure 1. Anterior view of the arteria lusoria. Black asterisk, aortic arch; black arrow, bicarotid trunk; white arrows, arteria lusoria; PT: pulmonary trunk; SVC: superior vena cava.

DISCUSSION

There are six aortic arches during embryonic development. Some of those arches are lost at different stages of embryogenesis. The fourth AA gives origin to the regular AA of the fetus. The RSA arises from the fourth arch, the right dorsal aorta and the right seventh intersegmental artery.^{13,14}

Essentially, the AL is a remnant of the right dorsal aorta caudal to the seventh intersegmental artery. This embryonic alteration is associated with disappearance of the normally patent right fourth AA and part of the right dorsal aorta cranial to the seventh intersegmental artery during embryogenesis.¹⁵

The AL was firstly described by Hunauld in 1735, although David Bayford described the first case of dysphagia lusoria in 1794. The word lusoria is derived from the Latin expression “*lusus naturae*,” which means “trick of nature”.³

According to the literature, incidence of the AL ranges from 0.2% to 3%.^{6,12,15-17} The trajectory of the AL can be retroesophageal (80-84%), pretracheal (4.2-5%), or passing between the two structures (12.7-15%).^{3,12}

Regarding its origin, it usually originates from the upper portion of the thoracic aorta or as the leftmost branch of the AA.^{1,12} Moreover, it can be dilated at its origin, forming a diverticulum known as “Kommerel’s Diverticulum,” first described by Burckhard F. Kommerell in 1936.³ The incidence of this diverticulum was reported as 60% by Myers et al.,³ although Polguy et al.¹² reports an incidence of 14.9% in a review of 141 cases.

Adachi and Williams classified the numerous variations of the AA branching pattern. They also classified the RSRA into four different types: 1) Type G-1, in which

the ARSA arises from the distal portion of the AA as its last branch. The other main branches have no variations; 2) Type CG-1, in which the ARSA originates from the distal portion of the AA and the left vertebral artery originates directly from the AA; 3) Type H-1, in which the AL also arises from the distal portion of the AA, although a bicarotid trunk is also present (as observed in this case); 4) Type N-1, in which there is a mirror image of type G, with a right-sided AA and the left subclavian artery mimicking the AL.^{10,18} Those types are illustrated in Figure 2.

A systematic review by Polguy et al.¹² reports a higher incidence of the AL in females (55.3%) than in males (44.7%). The AL is usually asymptomatic.^{3,12} The review showed that the most common symptoms are dysphagia (71.2%), dyspnea (18.7%), retrosternal pain (17.0%), coughing (7.6%), and weight loss (5.9%), although symptoms such as stomach-ache, back pain, and numbness of the right upper limb were also described.¹² Clinically, AL may mimic pericarditis, endocarditis, or aortic dissection.¹⁹

AL is usually seen together with other anatomical variations, such as bicarotid trunk, non-recurrent laryngeal nerve, and right-sided AA. Furthermore, it can be associated with many cardiac anomalies (aortic coarctation, interrupted AA, tetralogy of Fallot, truncus arteriosus, transposition of the great arteries, and ventricular and atrial septal defects), genetic disorders such as Downs', Edwards', and DiGeorge syndromes, aneurysms, and arterioesophageal fistula.^{3,8,9,12,20,21}

This vessel is of considerable surgical interest because of its spatial disposition, since it can be injured during many head and neck surgeries, such as lymph node dissection of the right paratracheal fossa or thyroidectomies, tracheotomy, and transradial coronary procedures.⁷⁻⁹ The AL can be used as a flap in order to treat aortic coarctation.²²

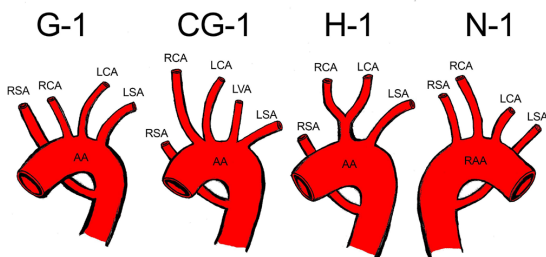


Figure 2. Schematic drawing based on the Adachi-Williams classification of right subclavian artery anomalies. AA: aortic arch; RAA: right aortic arch; RSA: right subclavian artery; RCA: right common carotid artery; LCA: left common carotid artery; LVA: left vertebral artery; LSA: left subclavian artery.

Dysphagia lusoria is usually treated with endovascular techniques, thoracic endografts and revascularization, ligation of the AL via left thoracotomy, and even embolization.^{12,16}

CONCLUSION

The AL is a clinically significant anatomical variation, since it can mimic many different diseases, as well as cause dysphagia in patients. Furthermore, presence of the AL seems to predispose to aneurysms. Knowledge of this variation is of crucial importance to radiologists, head and neck surgeons, vascular surgeons, and clinicians.

REFERENCES

1. Testut L, Latarjet A. *Tratado de anatomía humana*. Barcelona: Salvat; 1958.
2. Bergman R, Thompson S, Afifi A, Saadeh F. *Compendium of human anatomic variation: text, atlas, and world literature*. Baltimore: Urban & Schwarzenberg; 1988.
3. Myers PO, Fasel JH, Kalangos A, Gailloud P. Arteria lusoria: developmental anatomy, clinical, radiological and surgical aspects. *Ann Cardiol Angeiol*. 2010;59(3):147-54. PMID:19962688. <http://dx.doi.org/10.1016/j.ancard.2009.07.008>.
4. Abraham V, Mathew A, Cherian V, Chandran S, Mathew G. Aberrant subclavian artery: anatomical curiosity or clinical entity. *Int J Surg*. 2009;7(2):106-9. PMID:19246267. <http://dx.doi.org/10.1016/j.ijssu.2009.01.009>.
5. Derbel B, Saaidi A, Kasraoui R, et al. Aberrant right subclavian artery or arteria lusoria: a rare cause of dyspnea in children. *Ann Vasc Surg*. 2012;26(3):419e-14. PMID:22321486. <http://dx.doi.org/10.1016/j.avsg.2011.09.007>.
6. Reynolds I, McGarry J, Mullett H. Aberrant right retroesophageal subclavian artery causing esophageal compression. *Clin Case Rep*. 2015;3(10):897-8. PMID:26509033. <http://dx.doi.org/10.1002/ccr3.351>.
7. Desvant C, Chevalier D, Mortuaire G. Tracheotomy bleeding from an unusual tracheo-arterial fistula: involvement of an aberrant right subclavian artery. *J Laryngol Otol*. 2010;124(12):1333-6. PMID:20537208. <http://dx.doi.org/10.1017/S0022215110001362>.
8. Pan D, Cufari ME, Lim E. Beware of arteria lusoria during lymph node dissection of the right paratracheal fossa for lung cancer surgery. *J Thorac Dis*. 2014;6(12):E264-6. PMID:25590005.
9. Casal D, Peças A, Sousa D, Rosa-Santos J. A non-recurrent inferior laryngeal nerve in a man undergoing thyroidectomy: a case report. *J Med Case Reports*. 2010;4(1):386. PMID:21114813. <http://dx.doi.org/10.1186/1752-1947-4-386>.
10. Donadel MM, Lontra MB, Cavazzola LT, Corso CO. Retroesophageal right subclavian artery: a case report and a review of literature. *Eur J Anat*. 2006;10(3):57-60.
11. Bergwerff M, DeRuiter MC, Hall S, Poelmann RE, Gittenberger-de-Groot AC. Unique vascular morphology of the fourth aortic arches: possible implications for pathogenesis of type-B aortic arch interruption and anomalous right subclavian artery. *Cardiovasc Res*. 1999;44(1):185-96. PMID:10615402. [http://dx.doi.org/10.1016/S0008-6363\(99\)00186-8](http://dx.doi.org/10.1016/S0008-6363(99)00186-8).
12. Polguy M, Chrzanowski Ł, Kasprzak JD, Stefańczyk L, Topol M, Majos A. The aberrant right subclavian artery (arteria lusoria): the

- morphological and clinical aspects of one of the most important variations: a systematic study of 141 reports. *Sci World J.* 2014;2014:1-6. PMID:25105156. <http://dx.doi.org/10.1155/2014/292734>.
13. Kondori BJ, Asadi MH, Rahimian E, Tahsini MR. Anatomical variations in aortic arch branching pattern. *Arch Iran Med.* 2016;19(1):72-4. PMID:26702752.
 14. Schoenwolf GC, Bleyl SB, Brauer PR, Francis-West PH. Larsen's human embryology. 5th ed. New York: Churchill Livingstone; 2015.
 15. Kawai K, Honma S, Kumagai Y, Koba Y, Koizumi M. A schematic diagram showing the various components of the embryonic aortic arch complex in the retroesophageal right subclavian artery. *Anat Sci Int.* 2011;86(3):135-45. PMID:21246420. <http://dx.doi.org/10.1007/s12565-010-0101-7>.
 16. Jalaie H, Grommes J, Sailer A, et al. Treatment of symptomatic aberrant subclavian arteries. *Eur J Vasc Endovasc Surg.* 2014;48(5):521-6. PMID:25150442. <http://dx.doi.org/10.1016/j.ejvs.2014.06.040>.
 17. Tubbs RS, Oakes WJ, Salter EG, Zehner SJ. Retroesophageal right subclavian artery with persistent ductus arteriosus. *Anat Sci Int.* 2004;79(2):98-100. PMID:15218630. <http://dx.doi.org/10.1111/j.1447-073x.2004.00068.x>.
 18. Natsis KI, Tsiouridis IA, Didagelos MV, Fillipidis AA, Vlasis KG, Tsikaras PD. Anatomical variations in the branches of the human aortic arch in 633 angiographies: clinical significance and literature review. *Surg Radiol Anat.* 2009;31(5):319-23. PMID:19034377. <http://dx.doi.org/10.1007/s00276-008-0442-2>.
 19. Bisognano JD, Young B, Brown JM, Gill EA, Fang FC, Zisman LS. Diverse presentation of aberrant origin of the right subclavian artery. *Chest.* 1997;112(6):1693-7. PMID:9404777. <http://dx.doi.org/10.1378/chest.112.6.1693>.
 20. Feugier P, Lemoine L, Gruner L, Bertin-Maghit M, Rousselet B, Chevalier J-M. Arterioesophageal fistula: a rare complication of retroesophageal subclavian arteries. *Ann Vasc Surg.* 2003;17(3):302-5. PMID:12704542. <http://dx.doi.org/10.1007/s10016-001-0406-z>.
 21. Godlewski J, Widawski T, Michalak M, Kmieć Z. Aneurysm of the aberrant right subclavian artery: a case report. *Pol J Radiol.* 2010;75(4):47-50. PMID:22802805.
 22. Arrigoni SC, Willems TP, Mungropp HE, Van Den Heuvel F, Ebels T. Lusoria flap for the management of aortic coarctation in an eight-year-old child. *World J Pediatr Congenit Heart Surg.* 2013;4(3):302-4. PMID:24327502. <http://dx.doi.org/10.1177/2150135113480531>.

Correspondence

Carlos Alberto Araujo Chagas
 Universidade Federal Fluminense – UFF, Morphology Department
 Rua Professor Ernani Mello, 101 – São Domingos
 CEP 24210-150 - Niterói (RJ), Brazil
 Tel: +55 (21) 2629-2335 / +55 (21) 98821-0066
 E-mail: chagas@vm.uff.br

Author information

TFOL - Vascular surgeon from Universidade Estadual Paulista;
 Interventional radiologist and endovascular surgeon from
 Universidade de São Paulo; Research staff member, Grupo de
 Pesquisas em Ciências Médicas e Fisiopatologia Vascular (CAPES/
 CNPQ).
 LASP - Medical student, Universidade Federal Fluminense (UFF);
 Research staff member, Grupo de Pesquisas em Ciências Médicas e
 Fisiopatologia Vascular (CAPES/CNPQ).
 RC - Physical therapist from Universidade Estácio de Sá; PhD in
 Domestic and Wild Animal Anatomy from Universidade de São
 Paulo.
 MAB - PhD in Morphology from Universidade do Estado do Rio
 de Janeiro; Resident physician in Orthopedics and Traumatology,
 Hospital Municipal Salgado Filho; Associate professor, Universidade
 Federal Fluminense (UFF).
 CAAC - MSc in Morphological Sciences from Universidade Federal
 do Rio de Janeiro (UFRJ); Board-certified in Angiology by Pontifícia
 Universidade Católica do Rio de Janeiro (PUC-Rio); Lead researcher,
 Grupo de Pesquisas em Ciências Médicas e Fisiopatologia Vascular
 (CAPES/CNPQ); Adjunct professor, Universidade Federal Fluminense;
 Staff, Serviço de Angiologia, Hospital Geral da Santa Casa da
 Misericórdia do Rio de Janeiro.

Author contributions

Conception and design: CAAC, LASP, TFOL, RC
 Analysis and interpretation: CAAC, LASP, TFOL
 Data collection: CAAC, LASP, TFOL, RC
 Writing the article: CAAC, LASP, MAB, TFOL
 Critical revision of the article: CAAC, MAB, TFOL, RC
 Final approval of the article*: CAAC, LASP, MAB, TFOL, RC
 Statistical analysis: N/A.
 Overall responsibility: CAAC

*All authors have read and approved of the final version of the article submitted to *J Vasc Bras*.