

Case report: rupture of popliteal artery aneurysm

Relato de caso: aneurisma roto de artéria poplítea

Altino Ono Moraes¹, Rogério Yoshikazu Nabeshima¹, Felipe Franchini Rezende², Ericsson Fernando Viotto¹,
Claudio Ricardo Bogdan³

Abstract

An 83-year-old female patient with a history of prior endovascular treatment to repair an abdominal aortic aneurysm presented with intense pain and edema in the left leg, with hyperemia and localized temperature increase. Doppler ultrasonography revealed a voluminous aneurysm of the popliteal artery with a contained rupture, and hematoma involving the popliteal fossa and the medial and anterior surfaces of the knee causing compression of the popliteal vein. Endovascular repair was accomplished with covered stents and the rupture was confirmed. During the procedure the aneurysm was excluded and the signs and symptoms it had caused resolved completely, but during the postoperative period the patient developed sepsis of pulmonary origin and died.

Keywords: ruptured popliteal artery aneurysm; peripheral aneurysm; endovascular surgery; covered stent.

Resumo

Mulher de 83 anos, com tratamento endovascular prévio de aneurisma de aorta abdominal, iniciou com quadro de dor intensa e edema de perna esquerda, evoluindo com hiperemia e calor local. Ao exame eco-Doppler, apresentou aneurisma volumoso de artéria poplítea roto contido, com hematoma abrangendo fossa poplítea, nas faces medial e anterior de joelho, causando compressão da veia poplítea. Durante a correção endovascular com stent recoberto, foi confirmada a presença de rotura do aneurisma. O aneurisma foi excluído e a paciente teve regressão completa dos sinais e sintomas decorrentes dele; porém, evoluiu no pós-operatório com sepse de origem pulmonar e óbito.

Palavras-chave: aneurisma roto de artéria poplítea; aneurisma periférico; cirurgia endovascular; stent recoberto.

¹ Associação Beneficente Bom Samaritano, Maringá, PR, Brazil.

² Universidade Positivo – UP, Curitiba, PR, Brazil.

³ Faculdade Ingá – Uningá, Maringá, PR, Brazil.

Financial support: None.

Conflicts of interest: No conflicts of interest declared concerning the publication of this article.

Submitted: July 28, 2014. Accepted: December 24, 2014.

The study was carried out at Hospital e Maternidade Maringá, Maringá (PR), Brazil.

INTRODUCTION

Popliteal artery aneurysms (PAA) are responsible for 70 to 80% of cases of peripheral aneurysms. They have greatest incidence in men over 65 years of age and in 50% of cases they are bilateral.¹ While etiology is multifactorial, the most common agent is atherosclerosis; clinical diagnosis only occurs when arterial dilation has attained large dimensions or when ischemic complications in the limb emerge.² Clinical manifestations of PAA include acute arterial thrombosis, distal embolization, compression of veins and/or nerves and rupture, the last of which is a rare complication.¹

Nowadays, endovascular surgery has become established as an alternative treatment to open repair of PAA, since it offers certain advantages, such as reduced blood loss, more rapid postoperative recovery and earlier hospital discharge.^{3,4} We report a rare case of PAA rupture that was treated in the emergency room using endovascular techniques.

CASE DESCRIPTION

An 83-year-old female patient with prior history of endovascular repair of an abdominal aortic aneurysm was admitted 15 days after onset of significant pain and edema in the left lower limb. Physical examination revealed edema with pitting involving the left knee and leg, discrete hyperemia and localized temperature increase, in addition to a pulsating mass in the popliteal area (Figure 1). Doppler ultrasonography of the lower limbs revealed a voluminous aneurysm of the popliteal artery and hematoma involving the popliteal fossa and the medial and anterior surfaces of the knee, with images compatible with a contained rupture causing compression of the popliteal vein. The patient had presented at a different service with the rupture around a week previously and had been treated for erysipelas; she had a high surgical risk and considerable cardiac arrhythmia, in addition to anemia (her hemoglobin level was 10). Surgery was performed via anterograde puncture of the common femoral artery and the aneurysm was accessed using a hydrophilic guide wire and multi-purpose catheter; the proximal zone was assessed and two Gore Viabahn® covered stents were released and fitted with the aid of an angioplasty balloon. During the endovascular surgical procedure it was possible to observe that the aneurysm had ruptured and that after repair it was completely excluded (Figures 2 and 3). The patient required one bag of concentrated red blood cells during the procedure. The patient's signs and symptoms resolved completely after the procedure,

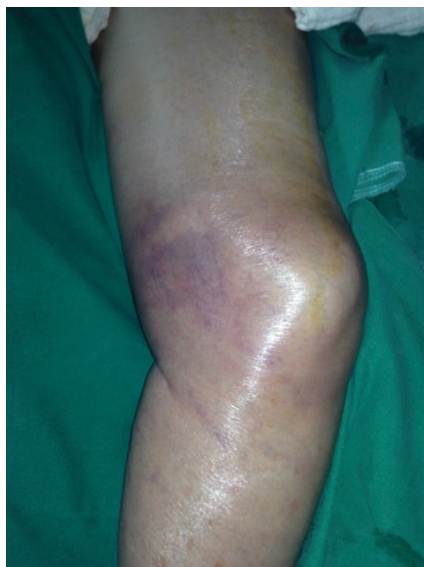

Figure 1. Preoperative presentation. Image of medial surface of the thigh, showing voluminous hematoma and ecchymosis of subcutaneous tissues.

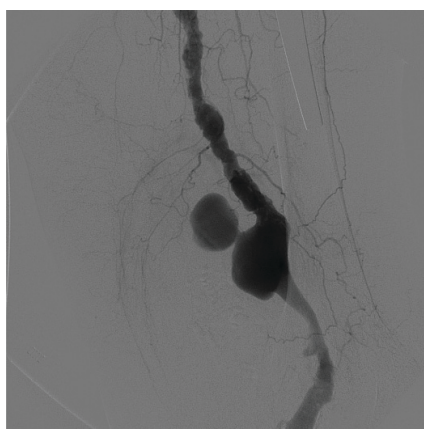


Figure 2. Intraoperative image showing aneurysm rupture, with contrast leakage, and its containment.

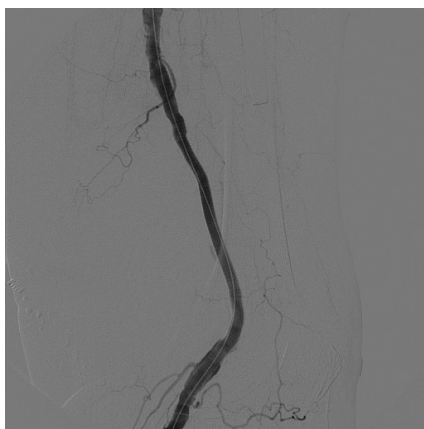

Figure 3. Intraoperative image after aneurysm repair using GORE® Viabahn stents.

but during the postoperative period she developed sepsis of pulmonary origin and died.

DISCUSSION

Popliteal artery aneurysms are the most common type of peripheral aneurysm and they are the second most frequent out of all different types of aneurysms, with only abdominal aortic aneurysms occurring more often.⁵ They are present in around 1% of the general population and are more common among males, over the age of 65 years, and in patients with several comorbidities.^{2,4-6}

The presence of a PAA is suggestive of the existence of aneurysms in other territories, particularly the contralateral popliteal arteries, the femoral and iliac arteries and the abdominal aorta.^{1,4,5,7} Popliteal artery aneurysms have multifactorial etiology and their cause has not been completely elucidated, although atherosclerosis is the favored hypothesis for elderly patients.⁷⁻⁹

Patients may be asymptomatic or they may present with ischemic symptoms related to thrombosis of the aneurysm or an embolic event secondary to it, which can occur in 33% of cases.⁷ The manifestations of ischemia are the same that result from any type of ischemic event, including pallor, low-temperature, absent pulses paresthesia and pain. Symptoms of nerve compression, such as tingling and burning sensations, or of venous pressure, such as edema and deep venous thrombosis, can also occur.⁵

In general, AAPs are responsible for high complication rates, varying from 68 to 77% of cases over 5 years. Rupture of a PAA occurs in 0.5 to 7% of cases.^{7,9,10} Up to 40 percent of patients can require lower limb amputation and life-threatening events occur in 5% of cases.⁷

Treatment consists of excluding the aneurysm in cases where diameter is greater than 2 cm, there is mural thrombus or torsion exceeds 45°. Bilateral cases and patients with concomitant arterial hypertension should also be treated because of the higher rates of complications.^{7,11,12}

This report describes the case of a woman with a ruptured popliteal artery aneurysm who was successfully treated using endovascular techniques to

place covered stents. The emergence of endovascular surgery as a treatment option is transforming care because it offers less perioperative blood loss and shorter hospital stays and recovery times, when compared with conventional open treatment.

REFERENCES

1. Thomazinho F, Silvestre JMS, Sardinha WE, Motta F, Perozin IS, Morais Filho D. Tratamento endovascular de aneurisma de artéria poplítea. *J Vasc Bras.* 2008;7(1):38-43. <http://dx.doi.org/10.1590/S1677-54492008000100007>.
2. Kauffman P, Puech-Leão P. Tratamento cirúrgico do aneurisma da artéria poplítea: experiência de 32 anos. *J Vasc Bras.* 2002;1(1):5-14.
3. Antonello M, Frigatti P, Battocchio P, et al. Open repair versus endovascular treatment for asymptomatic popliteal artery aneurysm: results of a prospective randomized study. *J Vasc Surg.* 2005;42(2):185-93. <http://dx.doi.org/10.1016/j.jvs.2005.04.049>. PMID:16102611
4. Meka M, Wixon CL, Mondy SJ, Busken C. Endovascular exclusion of ruptured popliteal artery aneurysm. *Am Surg.* 2010;76(3):338-9. PMID:20349671.
5. Imigo G F, Fonfah Z C, Massri E D, Sánchez C G, Sánchez H A. Aneurisma de artéria poplítea. *Cuad. Cir.* 2009;23(1):39-43. <http://dx.doi.org/10.4206/cuad.cir.2009.v23n1-08>.
6. Gao X, Qi L, Chen B, Yu H, Li J, Zhang J. A rare case of giant popliteal artery aneurysm in a young adult. *Vascular.* 2011;19(6):342-5. <http://dx.doi.org/10.1258/vasc.2010.cr0260>. PMID:21885475
7. Rojas-Reyna GA, Cervantes-Castro J, Alvarado-Bachmann R, Wellman-Wollenstein R, Cervera-Servin A. Aneurismas de la artéria poplítea. Treinta años de experiencia en el Centro Médico ABC. *Cir Cir.* 2008;76(1):55-9. PMID:18492421.
8. Ferreira M, Medeiros A, Monteiro M, Lanziotti L. Alternativa técnica no tratamento endovascular dos aneurismas da artéria poplítea. *J Vasc Bras.* 2008;7(1):44-8. <http://dx.doi.org/10.1590/S1677-54492008000100008>.
9. Rits Y, Erben Y, Ricotta JJ 2nd. Endovascular repair of a ruptured giant popliteal artery aneurysm. *Perspect Vasc Surg Endovasc Ther.* 2009;21(3):190-4. <http://dx.doi.org/10.1177/1531003509352097>. PMID:19965786
10. Marin ML, Veith FJ, Panetta TF, et al. Transfemoral endoluminal stented graft repair of a popliteal artery aneurysm. *J Vasc Surg.* 1994;19(4):754-7. [http://dx.doi.org/10.1016/S0741-5214\(94\)70052-4](http://dx.doi.org/10.1016/S0741-5214(94)70052-4). PMID:8164291
11. Verhoeven ELG, Tielliu IFJ, Kapma MR, Zeebregts CJ. Popliteal artery aneurysms: endovascular options. In: Greenhalgh RM, editor. *Towards vascular and endovascular consensus.* London: BIBA Medical; 2005. p. 538-546.
12. Hollier LH, Stanson AW, Gloviczki P, et al. Arteriomegaly: classification and morbid implications of diffuse aneurysmal disease. *Surgery.* 1983;93(5):700-8. PMID:6845177.

Correspondence

Altino Ono Moraes
Av. Cidade de Leiria, 445
CEP 87014-100 – Maringá (PR), Brazil
Tel: + 55 (44) 32246704 / +55 (44) 88024822
E-mail: altino_moraes@uol.com.br

Author information

AOM - MSc in Surgery from UNIFESP; Board-certified in Vascular Surgery from SBACV; preceptor and head of the Program of Medical Residence in Vascular Surgery, Associação Beneficente Bom Samaritano.

RYN - resident in Vascular Surgery from Associação Beneficente Bom Samaritano.

FFR - a medical student (6th year), Universidade Positivo.

EFV - Board-certified in Vascular Surgery from SBACV; preceptor of the Program of Medical Residence in Vascular Surgery, Associação Beneficente Bom Samaritano.

CRB - Board-certified in Vascular Surgery from SBACV; professor of Vascular Surgery, Uningá.

Author contributions

Conception and design: AOM

Analysis and interpretation: N/A.

Data collection: AOM, RYN, FFR

Surgical team: AOM, RYN, FFR, EFV, CRB

Writing the article: AOM, RYN, FFR

Critical revision of the article: AOM

Final approval of the article*: AOM, RYN, FFR, EFV, CRB

Statistical analysis: N/A.

Overall responsibility: AOM

* All authors have read and approved of the final version of the article submitted to J Vasc Bras.