

## Lemierre syndrome: a case report

### *Síndrome de Lemierre: relato de caso*

Carolina Parreira Ribeiro Camêlo<sup>1</sup>, Marcelo Luiz Brandão<sup>1</sup>, Ly de Freitas Fernandes<sup>1</sup>, Mônica Meireles Costa<sup>1</sup>, Ana Bittencourt Detanico<sup>1</sup>, Celso Luiz Lisita Filho<sup>1</sup>, Juliano Ricardo Santana dos Santos<sup>1</sup>

#### **Abstract**

Suppurative thrombophlebitis of the internal jugular vein, or Lemierre syndrome, was described for the first time in 1900. The most common initial event is an infection of the oropharynx associated with thrombosis of the internal jugular vein. While it is a rare entity, Lemierre syndrome remains a disease that causes considerable morbidity and mortality, due to its progression and to delays in diagnosis.

**Keywords:** venous thrombosis; jugular veins; Lemierre syndrome.

#### **Resumo**

A tromboflebite supurativa da veia jugular interna ou síndrome de Lemierre foi descrita pela primeira vez em 1900. O evento inicial mais frequente é a infecção de orofaringe associada à trombose da veia jugular interna. Embora uma entidade rara, a síndrome de Lemierre continua a ser uma doença de morbidade e mortalidade consideráveis devido à sua progressão e atrasos de diagnóstico.

**Palavras-chave:** trombose venosa; veias jugulares; síndrome de Lemierre.

<sup>1</sup>Hospital das Clínicas, Universidade Federal de Goiás - UFG, Goiânia, GO, Brazil.

Financial support: None.

Conflicts of interest: No conflicts of interest declared concerning the publication of this article.

Submitted: January 22, 2015. Accepted: March 17, 2015.

The study was carried out at Hospital das Clínicas, Universidade Federal de Goiás (UFG), Goiânia, GO, Brazil.

## ■ INTRODUCTION

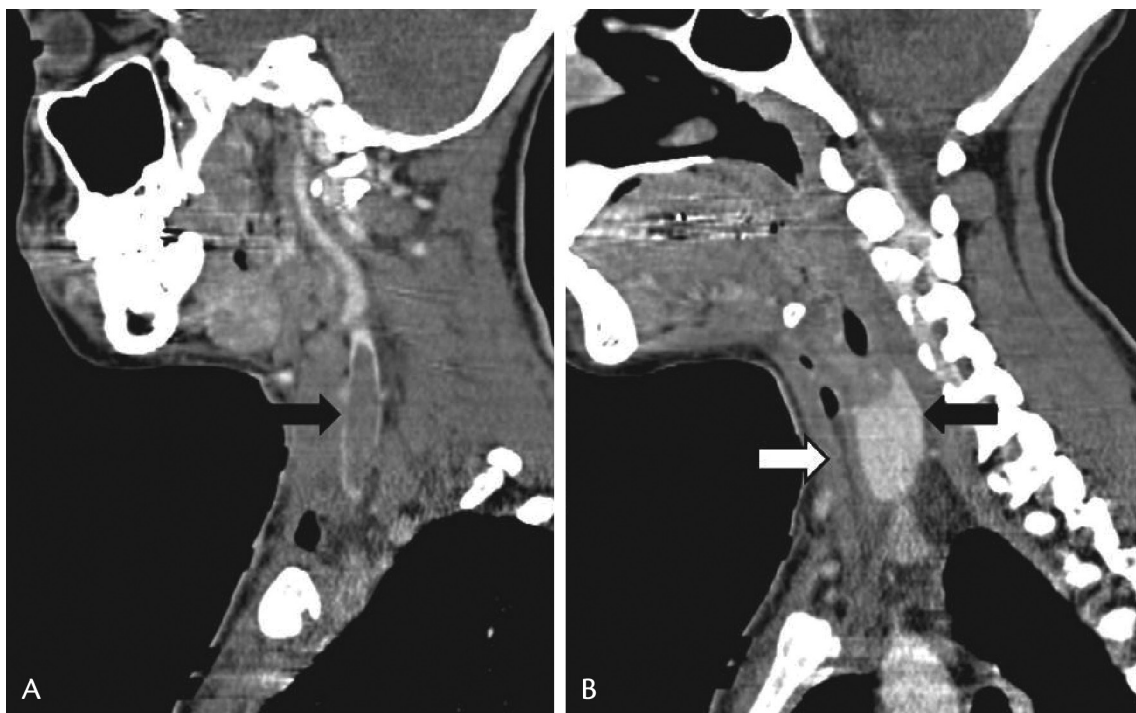
A syndrome that was first described in 1900 by Courmont and Cade, and then once more in 1918 by Schottmuller, was finally named in 1936 by the French microbiologist Dr. Andre Lemierre, who also described the disease process better. In 1936, Lemierre published a pioneering article in which he wrote about 20 patients with anaerobic sepsis all of whom had had an oropharyngeal infection and then developed septic thrombophlebitis of the internal jugular vein and metastatic abscesses, the majority in the lungs and major joints. According to Lemierre, the clinical findings were so characteristic that it was possible to make a diagnosis without the results of any type of bacterial testing, including blood cultures.<sup>1,2</sup>

The incidence of Lemierre syndrome has been estimated at between 0.6 and 2.3 per million, with mortality rates from 4 to 18%.<sup>3</sup> *Fusobacterium necrophorum* has been described as the most common causative agent, with positive cultures in 81.7% of patients, according to a study conducted by Chirinos et al.<sup>4</sup>

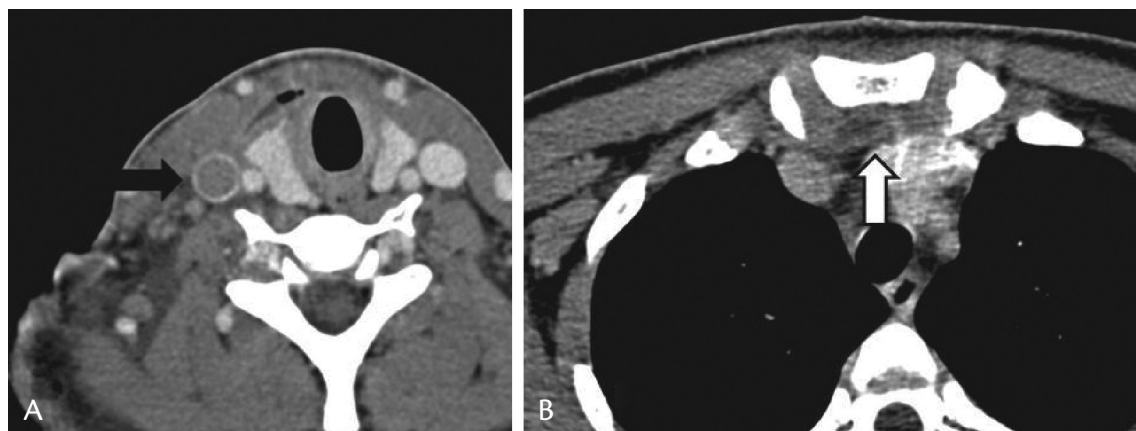
## ■ CASE REPORT

A 17-year-old female patient was admitted to hospital with peritonsillar abscess. Symptoms had emerged 3 days previously with odynophagia, fever

and prostration. She had visited the health center during the 3 days since onset and had been prescribed analgesics and benzathine penicillin. The patient continued to worsen, and tumors began to appear in the right cervical region and on the fourth day the patient was referred to a tertiary hospital. The peritonsillar abscess was drained and a sample was cultured and antibiotic therapy with amoxicillin-clavulanate was started. The patient was seen again 3 days after hospital admission because her condition had worsened further still and the antibiotic was substituted with ceftriaxone and clindamycin. A tomography of the cervical and thoracic region showed collection in the cervical visceral space, in the prevascular mediastinum, and thrombosis of the right internal jugular vein, as shown in Figures 1 and 2. Anticoagulation treatment was started because the patient's condition was still deteriorating, despite receiving optimum clinical treatment. The culture results identified GRAM positive cocci. Serology was negative for hepatitis B and C, HIV and VDRL and an Epstein Barr virus test was also negative. The patient began to improve progressively. Two weeks later she was discharged from hospital and antibiotic therapy was continued for another 4 weeks and anticoagulation prescribed for 3 months. Follow-up revealed good progress.



**Figure 1. A)** Coronal cervical computed tomography showing thrombosis of the right internal jugular vein (black arrow); **B)** Coronal cervical computed tomography showing thrombosis of the right internal jugular vein (black arrow) and perivascular collection (white arrow).



**Figure 2. A)** Axial cervical computed tomography showing thrombosis of the right internal jugular vein (black arrow); **B)** Axial cervical computed tomography showing perivascular collection in the mediastinum (white arrow).

## DISCUSSION

The reemergence of this once forgotten disease is the result of discouraging treatment of acute tonsillitis with penicillin and of improved diagnosis and blood culture methods.

The syndrome begins with the symptoms of an oropharyngeal infection, which may have abated before the disease progresses, even in the absence of antibiotic treatment.<sup>5,6</sup> The second phase of the infection involves invasion of the lateral pharynx and can cause a range of additional clinical manifestations, depending on the site of invasion. Invasion of the anterior compartment can lead to vascular involvement, while invasion of the posterior compartment can cause paralysis of cranial nerves X-XII or Horner syndrome.<sup>4</sup>

Thrombophlebitis of the internal jugular vein often manifests with unilateral pain and edema at the angle of the mandible and along the length of the sternocleidomastoid muscle and is occasionally associated with trismus.<sup>7,8</sup> One study<sup>4</sup> reported that dysphagia occurs in up to 17.4% of patients. Sternocleidomastoid muscle spasm is also possible and paralysis of the trapezoid muscle was reported in one case.<sup>5</sup> During metastatic propagation, septic emboli may provoke characteristic clinical findings, depending on the site of embolization.

Embolic disease in the lungs occurs as a rule, and this is the most common site of metastatic propagation (97%), with symptoms that are similar to those of bilateral pulmonary embolism with aseptic nodular infiltrate and occasional cavitation. Concomitant pleural effusion is common. Abscesses, empyema, pneumothorax and pneumatocele have also been described.<sup>6,7,9-11</sup> According to one study,<sup>4</sup> respiratory insufficiency can occur in up to 15.5% of cases.

Lemierre syndrome should be suspected when faced with septic pulmonary emboli and persistent fever even after antibiotic therapy is given. In general, clinical suspicion should be aroused when a patient with any type of infection of the head and neck develops signs of thrombophlebitis of the internal jugular vein, sepsis, or propagation of septic emboli to distant organs.<sup>12</sup>

Metastatic abscesses may occur, most frequently in the lungs and major joints. However, there are also descriptions in the literature of involvement of other sites, such as meninges, central nervous system, soft tissues and bones, causing hepatic and splenic abscesses, osteomyelitis, meningitis, cerebral infarction, thrombosis of the cavernous sinus, epidural abscesses and diffuse encephalopathy.<sup>13</sup>

Diagnosis should begin with identification of the microorganism responsible, by blood culture, aspiration of the thrombosed vein or direct culture of the vein.<sup>14</sup> Definitive diagnosis can be achieved using computed tomography, phlebography, simple echography or duplex echography. Contrast computed tomography (CCT) is the most useful examination for diagnosis, revealing edema of soft tissues and filling defects, or even the thrombus itself inside the internal jugular vein.

There is little reported experience of using magnetic resonance imaging (MRI), but it can be of great utility. Simple echography and, primarily, duplex echography can reveal thrombosis and show the extent of the thrombus. Phlebography can also detect the thrombosis, and can be employed when other methods are not available or in cases of diagnostic doubt.<sup>6,15</sup>

Duplex echography is a readily-available examination that is inexpensive, avoids the use of ionizing radiation and will show the majority of thrombi. Confirmatory

findings are presence of noncompressible thrombus, often associated with venous distention, and absent flow. Findings of total or partial loss of cardiac pulsation and respiratory phasicity on Doppler can alert the operator to the presence of thrombi in regions inaccessible to ultrasound, such as the clavicular region, the angle of the mandible and the base of the skull.

On the other hand, CCT and MRI make it possible to view the whole of the internal jugular vein and evaluate the proximal extent of thrombi in thoracic areas. Computed tomography with contrast will characteristically show distended veins, reinforced walls, low attenuation, intraluminal filling defects and soft tissue edema. If a diagnosis of Lemierre syndrome is suspected clinically or on the basis of a cervical CCT, this should be conducted at same time as the CCT of the chest. The sensitivity to flow and excellent soft tissue contrast of MRI makes it an effective method for identification and characterization of thrombi, although cost and availability currently limit its use. Radiological investigation is of fundamental importance to arriving at a specific diagnosis of Lemierre syndrome. Both CCT and duplex echography of the internal jugular veins are sensitive for detecting thrombosis of the internal jugular vein; evidence of septic pulmonary embolism during CCT may be the principal clue to the correct diagnosis.<sup>6</sup>

Treatment is based on antibiotic therapy, although there is no definitive therapeutic protocol and duration of treatment is a controversial subject. As soon as Lemierre syndrome is suspected, antibiotic coverage should be widened to include anaerobic organisms and should last from 3 to 6 weeks or until pulmonary abscesses are seen to have disappeared on tomography.<sup>15</sup> Surgical exploration and drainage of the peritonsillar abscesses may be indicated.<sup>16</sup>

Use of anticoagulants for Lemierre syndrome remains controversial. According to Amaro et al., routine anticoagulation is not advisable, because of the risk of hematogenous dissemination of the infection, and should be reserved for cases in which there is retrograde propagation of the thrombus in the direction of the cavernous sinus.<sup>13,17</sup> Ridgway et al. have pointed out that there are differing points of view with relation to using anticoagulation.<sup>12,18-20</sup> The mechanism of clot formation is secondary to an inflammatory process, especially in the internal jugular veins. Patients are not generally at increased risk of coagulopathy after resolution of Lemierre syndrome, but patients have exhibited increased factor VIII and antiphospholipid antibodies.

Those who are against anticoagulation therapy argue that the thrombi formed in Lemierre syndrome undergo

spontaneous resolution with good results for the patient. However, those who are in favor of anticoagulation support its use to achieve more rapid resolution of the thrombosis. Given the severity of the majority of patients' cases and the morbidity associated with it, it is believed that anticoagulation is of significant importance for accelerating resolution of septic thrombi.<sup>12</sup> Along the same lines, Hernández et al.<sup>21</sup> used anticoagulation only for cases in which sepsis relapsed and there was recent septic emboli formation, despite antibiotic treatment. However, the beneficial effects obtained by anticoagulation have been demonstrated in septic thrombophlebitis of major vessels.<sup>22</sup> This is why anti-coagulation for at least 3 months was chosen in the case described here. If the condition does not improve, ligation of the internal jugular vein is indicated.<sup>21</sup>

In Lemierre's day, ligation or excision of the internal jugular vein was practiced routinely, but nowadays its use is restricted to patients with septic embolization that persists after treatment with antibiotics.

## CONCLUSIONS

Opportune recognition of disease progression is crucial to prevention of the severe systemic manifestations by avoiding delayed diagnosis. There is consensus on using wide-spectrum antibiotics with coverage for anaerobics. However, therapeutic anticoagulation is still a controversial subject among vascular surgeons, but indication of therapeutic anticoagulation for all patients diagnosed with Lemierre syndrome predominates in the literature.

## REFERENCES

1. Courmont P, Cade A. Sur une septic-pyohemie de l'homme stimulant a peste et cause par un streptobacille anerobie. Arch Med Exp Anat Pathol. 1900;4.
2. Lemierre A. On certain septicaemias due to anaerobic organisms. Lancet. 1936;1(5874):701-3. [http://dx.doi.org/10.1016/S0140-6736\(00\)57035-4](http://dx.doi.org/10.1016/S0140-6736(00)57035-4).
3. Syed MI, Baring D, Addidle M, Murray C, Adams C. Lemierre syndrome: two cases and a review. Laryngoscope. 2007;117(9):1605-10. <http://dx.doi.org/10.1097/MLG.0b013e318093ee0e>. PMID:17762792.
4. Chirinos JA, Lichtstein DM, Garcia J, Tamariz LJ. The evolution of Lemierre syndrome: report of 2 cases and review of the literature. Medicine. 2002;81(6):458-65. <http://dx.doi.org/10.1097/00005792-200211000-00006>. PMID:12441902.
5. Agarwal R, Arunachalam PS, Bosman DA. Lemierre's syndrome: a complication of acute oropharyngitis. J Laryngol Otol. 2000;114(7):545-7. <http://dx.doi.org/10.1258/0022215001906110>. PMID:10992941.
6. Screamon NJ, Ravenel JG, Lehner PJ, Heitzman ER, Flower CD. Lemierre syndrome: forgotten but not extinct--report of four cases. Radiology. 1999;213(2):369-74. <http://dx.doi.org/10.1148/radiology.213.2.r99nv09369>. PMID:10551214.

7. Lao Luque J, Molina Utrilla R, Lorente Guerrero J, Mateu Vallverdú F, Perelló Scherdel E. Síndrome de Lemierre: a propósito de un caso. *An Otorrinolaringol Ibero Am.* 1993;20(6):599-605. PMID:8135336.
8. Carlson ER, Bergamo DF, Coccia CT. Lemierre's syndrome: two cases of a forgotten disease. *J Oral Maxillofac Surg.* 1994;52(1):74-8. [http://dx.doi.org/10.1016/0278-2391\(94\)90019-1](http://dx.doi.org/10.1016/0278-2391(94)90019-1). PMID:8263648.
9. Seidenfeld SM, Sutker WL, Luby JP. Fusobacterium necrophorum septicemia following oropharyngeal infection. *JAMA.* 1982;248(11):1348-50. <http://dx.doi.org/10.1001/jama.1982.03330110044024>. PMID:6955528.
10. Garrido JA, Ponte MC, Fernandez ML. Síndrome de Lemierre (sepsis postangina): una infección olvidada. *Med Clin.* 1989;93:660-2.
11. Cosgrove EF, Colodny SM, Pesce RR. Adult respiratory distress syndrome as a complication of postanginal sepsis. *Chest.* 1993;103(5):1628-9. <http://dx.doi.org/10.1378/chest.103.5.1628>. PMID:8486067.
12. Ridgway JM, Parikh DA, Wright R, et al. Lemierre syndrome: a pediatric case series and review of literature. *Am J Otolaryngol.* 2010;31(1):38-45. <http://dx.doi.org/10.1016/j.amjoto.2008.09.006>. PMID:19944898.
13. Amaro C, Pissarra C, Salvado C, et al. Síndrome de Lemierre: um caso clínico. *Med Interna.* 2005;12(4):225-9.
14. Andes DR, Urban AW, Acher CW, Maki DG. Septic thrombosis of the basilic, axillary, and subclavian veins caused by a peripherally inserted central venous catheter. *Am J Med.* 1998;105(5):446-50. [http://dx.doi.org/10.1016/S0002-9343\(98\)00287-3](http://dx.doi.org/10.1016/S0002-9343(98)00287-3). PMID:9831430.
15. Handa GI, Bertuzzo GS, Muller KS, et al. Síndrome de Lemierre. *J Vasc Bras.* 2010;9(1):82-5.
16. Sinave CP, Hardy GJ, Fardy PW. The Lemierre syndrome: suppurative thrombophlebitis of the internal jugular vein secondary to oropharyngeal infection. *Medicine.* 1989;68(2):85-94. <http://dx.doi.org/10.1097/00005792-198903000-00002>. PMID:2646510.
17. Kristensen LH, Prag J. Human necrobacillosis, with emphasis on Lemierre's syndrome. *Clin Infect Dis.* 2000;31(2):524-32. <http://dx.doi.org/10.1086/313970>. PMID:10987717.
18. Barker J, Winer-Muram HT, Grey SW. Lemierre syndrome. *South Med J.* 1996;89(10):1021-3. <http://dx.doi.org/10.1097/00007611-199610000-00021>. PMID:8865803.
19. Monge M, Aubry P, Dayen C, et al. [Lemierre syndrome: unusual, but still possible]. *Ann Med Interne.* 2003;154(4):263-6. PMID:14593318.
20. Goldenberg NA, Knapp-Clevenger R, Hays T, Manco-Johnson MJ. Lemierre's and Lemierre's-like syndromes in children: survival and thromboembolic outcomes. *Pediatrics.* 2005;116(4):e543-8. <http://dx.doi.org/10.1542/peds.2005-0433>. PMID:16147971.
21. Hernández MH, Canadas O, Casado M. Síndrome de Lemierre. Madrid: Centro de Salud Casa de Campo; 2008. p. 593-5.
22. Merlo González VE, Martín Parra C, Marina Martínez L, Ayensa Rincón A, Moreno Otero JA, Aguilar Florit J. Tromboflebitis séptica de la vena yugular interna secundaria a patología orofaríngea. *Med Intensiva.* 1998;22:78-80.

---

**Correspondence**

Carolina Parreira Ribeiro Camêlo  
 Rua 9-B, 223, Edifício Madre Paulina, apt. 1101 - Setor Oeste  
 CEP 74110-120 - Goiânia (GO), Brazil  
 Tel.: +55 (62) 8406-6608  
 E-mail: carolprcamelo@hotmail.com

**Author information**

CPRC - Resident in Vascular Surgery at Hospital das Clínicas, Universidade Federal de Goiás (UFG).  
 MLB - PhD in Vascular Surgery from Hospital das Clínicas, Universidade Federal de Goiás; Chief of the residence program in Vascular Surgery at Universidade Federal de Goiás (UFG).  
 LFF - MSc in Vascular Surgery from Hospital das Clínicas, Universidade Federal de Goiás; Professor of the internship and residence program in Vascular Surgery at Hospital das Clínicas, Universidade Federal de Goiás (UFG).  
 MMC - Part of the staff of the residence program in Vascular Surgery at Hospital das Clínicas, Universidade Federal de Goiás (UFG).  
 ABD, CLLF and JRSS - Residents in Vascular Surgery at Hospital das Clínicas, Universidade Federal de Goiás (UFG).

**Author contributions**

Conception and design: CPRC  
 Analysis and interpretation: CPRC, ABD, CLLF, JRSS  
 Data collection: CPRC, ABD, CLLF, JRSS  
 Writing the article: CPRC  
 Critical revision of the article: MLB, LFF, MMC  
 Final approval of the article\*: MLB  
 Statistical analysis: N/A  
 Overall responsibility: CPRC

\*All authors have read and approved of the final version of the article submitted to *J Vasc Bras.*